

World Journal of *Clinical Cases*

World J Clin Cases 2022 December 6; 10(34): 12462-12803



FIELD OF VISION

- 12462 Problematics of neurosurgical service during the COVID-19 pandemic in Slovenia
Munda M, Bosnjak R, Velnar T

MINIREVIEWS

- 12470 Circulating angiotensin converting enzyme 2 and COVID-19
Leowattana W, Leowattana T, Leowattana P
- 12484 Evaluation of gut dysbiosis using serum and fecal bile acid profiles
Monma T, Iwamoto J, Ueda H, Tamamushi M, Kakizaki F, Konishi N, Yara S, Miyazaki T, Hirayama T, Ikegami T, Honda A
- 12494 Pediatric kidney transplantation during the COVID-19 pandemic
Tamura H

ORIGINAL ARTICLE**Clinical and Translational Research**

- 12500 *Coptis*, *Pinellia*, and *Scutellaria* as a promising new drug combination for treatment of *Helicobacter pylori* infection
Yu Z, Sheng WD, Yin X, Bin Y

Case Control Study

- 12515 Effects of illness perception on negative emotions and fatigue in chronic rheumatic diseases: Rumination as a possible mediator
Lu Y, Jin X, Feng LW, Tang C, Neo M, Ho RC

Retrospective Study

- 12532 Significance of incidental focal fluorine-18 fluorodeoxyglucose uptake in colon/rectum, thyroid, and prostate: With a brief literature review
Lee H, Hwang KH
- 12543 Follow-up study on ThinPrep cytology test-positive patients in tropical regions
Chen YC, Liang CN, Wang XF, Wang MF, Huang XN, Hu JD
- 12551 Effect of teach-back health education combined with structured psychological nursing on adverse emotion and patient cooperation during ^{99m}Tc -3PRGD2.SPECT/CT
Gong WN, Zhang YH, Niu J, Li XB
- 12559 Nosocomial infection and spread of SARS-CoV-2 infection among hospital staff, patients and caregivers
Cheng CC, Fann LY, Chou YC, Liu CC, Hu HY, Chu D

Observational Study

- 12566** Effectiveness and safety of generic and brand direct acting antivirals for treatment of chronic hepatitis C
Abdulla M, Al Ghareeb AM, Husain HAHY, Mohammed N, Al Qamish J
- 12578** Influence of group B streptococcus and vaginal cleanliness on the vaginal microbiome of pregnant women
Liao Q, Zhang XF, Mi X, Jin F, Sun HM, Wang QX

Randomized Controlled Trial

- 12587** Clinical study on tri-tongue acupuncture combined with low-frequency electrical stimulation for treating post-stroke dysarthria
Man B, Li WW, Xu JF, Wang Q

META-ANALYSIS

- 12594** Three-dimensional time-of-flight magnetic resonance angiography combined with high resolution T2-weighted imaging in preoperative evaluation of microvascular decompression
Liang C, Yang L, Zhang BB, Guo SW, Li RC

CASE REPORT

- 12605** Acute cytomegalovirus hepatitis in an immunocompetent patient: A case report
Wang JP, Lin BZ, Lin CL, Chen KY, Lin TJ
- 12610** Long-term results of extended Boari flap technique for management of complete ureteral avulsion: A case report
Zhong MZ, Huang WN, Huang GX, Zhang EP, Gan L
- 12617** Amyloid β -related angiitis of the central nervous system occurring after COVID-19 vaccination: A case report
Kizawa M, Iwasaki Y
- 12623** Pseudoileus caused by primary visceral myopathy in a Han Chinese patient with a rare MYH11 mutation: A case report
Li N, Song YM, Zhang XD, Zhao XS, He XY, Yu LF, Zou DW
- 12631** Emergent use of tube tip in pharynx technique in "cannot intubate cannot oxygenate" situation: A case report
Lin TC, Lai YW, Wu SH
- 12637** Inflammatory myofibroblastic tumor of the central nervous system: A case report
Su ZJ, Guo ZS, Wan HT, Hong XY
- 12648** Atypical aggressive vertebral hemangioma of the sacrum with postoperative recurrence: A case report
Wang GX, Chen YQ, Wang Y, Gao CP
- 12654** Closed reduction of hip dislocation associated with ipsilateral lower extremity fractures: A case report and review of the literature
Xu Y, Lv M, Yu SQ, Liu GP

- 12665** Repair of a large patellar cartilage defect using human umbilical cord blood-derived mesenchymal stem cells: A case report
Song JS, Hong KT, Song KJ, Kim SJ
- 12671** Abdominal bronchogenic cyst: A rare case report
Li C, Zhang XW, Zhao CA, Liu M
- 12678** Malignant fibrous histiocytoma of the axilla with breast cancer: A case report
Gao N, Yang AQ, Xu HR, Li L
- 12684** Rapid hemostasis of the residual inguinal access sites during endovascular procedures: A case report
Kim H, Lee K, Cho S, Joh JH
- 12690** Formation of granulation tissue on bilateral vocal cords after double-lumen endotracheal intubation: A case report
Xiong XJ, Wang L, Li T
- 12696** Giant cellular leiomyoma in the broad ligament of the uterus: A case report
Yan J, Li Y, Long XY, Li DC, Li SJ
- 12703** Pomolidomide for relapsed/refractory light chain amyloidosis after resistance to both bortezomib and daratumumab: A case report
Li X, Pan XH, Fang Q, Liang Y
- 12711** Ureteral- artificial iliac artery fistula: A case report
Feng T, Zhao X, Zhu L, Chen W, Gao YL, Wei JL
- 12717** How to manage isolated tension non-surgical pneumoperitonium during bronchoscopy? A case report
Baima YJ, Shi DD, Shi XY, Yang L, Zhang YT, Xiao BS, Wang HY, He HY
- 12726** Amiodarone-induced muscle tremor in an elderly patient: A case report
Zhu XY, Tang XH, Yu H
- 12734** Surgical treatment of Pitt-Hopkins syndrome associated with strabismus and early-onset myopia: Two case reports
Huang Y, Di Y, Zhang XX, Li XY, Fang WY, Qiao T
- 12742** Massive low-grade myxoid liposarcoma of the floor of the mouth: A case report and review of literature
Kugimoto T, Yamagata Y, Ohsako T, Hirai H, Nishii N, Kayamori K, Ikeda T, Harada H
- 12750** Gingival enlargement induced by cyclosporine in Medullary aplasia: A case report
Victory Rodríguez G, Ruiz Gutiérrez ADC, Gómez Sandoval JR, Lomeli Martínez SM
- 12761** Compound heterozygous mutations in PMFBP1 cause acephalic spermatozoa syndrome: A case report
Deng TQ, Xie YL, Pu JB, Xuan J, Li XM
- 12768** Colonic tubular duplication combined with congenital megacolon: A case report
Zhang ZM, Kong S, Gao XX, Jia XH, Zheng CN

- 12775** Perforated duodenal ulcer secondary to deferasirox use in a child successfully managed with laparoscopic drainage: A case report
Alshehri A, Alsinan TA
- 12781** Complication after nipple-areolar complex tattooing performed by a non-medical person: A case report
Byeon JY, Kim TH, Choi HJ
- 12787** Interventional urethral balloon dilatation before endoscopic visual internal urethrotomy for post-traumatic bulbous urethral stricture: A case report
Ha JY, Lee MS
- 12793** Regression of gastric endoscopic submucosal dissection induced polypoid nodular scar after *Helicobacter pylori* eradication: A case report
Jin BC, Ahn AR, Kim SH, Seo SY
- 12799** Congenital absence of the right coronary artery: A case report
Zhu XY, Tang XH

ABOUT COVER

Editorial Board Member of *World Journal of Clinical Cases*, Giuseppe Lanza, MD, MSc, PhD, Associate Professor, Department of Surgery and Medical-Surgical Specialties, University of Catania, Catania 95123, Italy.
glanza@oasi.en.it

AIMS AND SCOPE

The primary aim of *World Journal of Clinical Cases* (*WJCC*, *World J Clin Cases*) is to provide scholars and readers from various fields of clinical medicine with a platform to publish high-quality clinical research articles and communicate their research findings online.

WJCC mainly publishes articles reporting research results and findings obtained in the field of clinical medicine and covering a wide range of topics, including case control studies, retrospective cohort studies, retrospective studies, clinical trials studies, observational studies, prospective studies, randomized controlled trials, randomized clinical trials, systematic reviews, meta-analysis, and case reports.

INDEXING/ABSTRACTING

The *WJCC* is now abstracted and indexed in Science Citation Index Expanded (SCIE, also known as SciSearch®), Journal Citation Reports/Science Edition, Current Contents®/Clinical Medicine, PubMed, PubMed Central, Scopus, Reference Citation Analysis, China National Knowledge Infrastructure, China Science and Technology Journal Database, and Superstar Journals Database. The 2022 Edition of Journal Citation Reports® cites the 2021 impact factor (IF) for *WJCC* as 1.534; IF without journal self cites: 1.491; 5-year IF: 1.599; Journal Citation Indicator: 0.28; Ranking: 135 among 172 journals in medicine, general and internal; and Quartile category: Q4. The *WJCC*'s CiteScore for 2021 is 1.2 and Scopus CiteScore rank 2021: General Medicine is 443/826.

RESPONSIBLE EDITORS FOR THIS ISSUE

Production Editor: *Si Zhao*; Production Department Director: *Xu Guo*; Editorial Office Director: *Jin-Lei Wang*.

NAME OF JOURNAL

World Journal of Clinical Cases

ISSN

ISSN 2307-8960 (online)

LAUNCH DATE

April 16, 2013

FREQUENCY

Thrice Monthly

EDITORS-IN-CHIEF

Bao-Gan Peng, Jerzy Tadeusz Chudek, George Kontogeorgos, Maurizio Serati, Ja Hyeon Ku

EDITORIAL BOARD MEMBERS

<https://www.wjgnet.com/2307-8960/editorialboard.htm>

PUBLICATION DATE

December 6, 2022

COPYRIGHT

© 2022 Baishideng Publishing Group Inc

INSTRUCTIONS TO AUTHORS

<https://www.wjgnet.com/bpg/gerinfo/204>

GUIDELINES FOR ETHICS DOCUMENTS

<https://www.wjgnet.com/bpg/GerInfo/287>

GUIDELINES FOR NON-NATIVE SPEAKERS OF ENGLISH

<https://www.wjgnet.com/bpg/gerinfo/240>

PUBLICATION ETHICS

<https://www.wjgnet.com/bpg/GerInfo/288>

PUBLICATION MISCONDUCT

<https://www.wjgnet.com/bpg/gerinfo/208>

ARTICLE PROCESSING CHARGE

<https://www.wjgnet.com/bpg/gerinfo/242>

STEPS FOR SUBMITTING MANUSCRIPTS

<https://www.wjgnet.com/bpg/GerInfo/239>

ONLINE SUBMISSION

<https://www.f6publishing.com>

Complication after nipple-areolar complex tattooing performed by a non-medical person: A case report

Je Yeon Byeon, Tae Hoon Kim, Hwan-Jun Choi

Specialty type: Medicine, research and experimental

Provenance and peer review: Unsolicited article; Externally peer reviewed.

Peer-review model: Single blind

Peer-review report's scientific quality classification

Grade A (Excellent): 0
Grade B (Very good): B
Grade C (Good): 0
Grade D (Fair): D
Grade E (Poor): 0

P-Reviewer: Agrawal P, United States; Touihmi S, Morocco

Received: September 25, 2022

Peer-review started: September 25, 2022

First decision: October 12, 2022

Revised: October 14, 2022

Accepted: November 7, 2022

Article in press: November 7, 2022

Published online: December 6, 2022



Je Yeon Byeon, Tae Hoon Kim, Hwan-Jun Choi, Plastic and Reconstructive Surgery, Soonchunhyang University Hospital, Cheonan KS002, South Korea

Corresponding author: Hwan-Jun Choi, MD, PhD, Professor, Surgeon, Plastic and Reconstructive Surgery, Soonchunhyang University Hospital, Soonchunhyang 6 gil 31, Bongmyeong-dong, Dongnam-gu, Cheonan-si, Chungcheongnam-do, Cheonan KS002, South Korea. iprskorea@gmail.com

Abstract

BACKGROUND

Compared to earlier, there has been an increase in the tattoo procedures for cosmetic purposes; and there has also been an increase in the tattoo procedures performed by non-medical personnel. In South Korea, only tattoos performed by a doctor are considered legal; however, there is still some debate over whether tattoo procedures performed by non-healthcare providers should be considered legal.

CASE SUMMARY

A 28-year-old woman visited our hospital with pain in both nipples and heat sensation over the last 4 d. She had a history of a nipple tattoo performed by an unlicensed person. Pinpoint bleeding was noted in both areolar areas, and the exudate mixed with pus and orange color ink was discharged. Oral medication and tulle with foam dressing were performed under the impression of cellulitis and allergic reaction. After 4 wk, nipples remained dark brown in color, resulting in a color mismatch between the nipple and orange-colored areola. The size of the areola was also found to be distinctly asymmetrical after healing. This complication may have been caused by the use of illegal ink or unsanitary procedures, or a problem may have occurred in the post-tattoo management stage.

CONCLUSION

Doctors use approved ink, aseptic procedure and appropriate postoperative care, and appropriate management can be performed in case of complications.

Key Words: Infections; Nipples; Tattooing; Licensure; Case report

©The Author(s) 2022. Published by Baishideng Publishing Group Inc. All rights reserved.

Core Tip: Tattoos are restricted in some cultures, or they are regulated by national policies. In the case of South Korea, it is stipulated by law that only a doctor can perform tattoo procedures. Nevertheless, as the accessibility and demand for tattoos increase among the people, illegal tattoo procedures are increasing. The author presents complications that occurred after illegal tattoo procedures. The use of unapproved dyes, unsanitary procedures, and the absence of post-treatment can result in unnatural and ugly tattoos. Tattoos can be performed more beautifully and naturally by a doctor, especially by a plastic surgeon. In particular, tattoos for cosmetic purposes can produce better results than those performed by non-medical personnel. Therefore, doctors' interest and participation in tattoos are necessary, and government regulations are also necessary.

Citation: Byeon JY, Kim TH, Choi HJ. Complication after nipple-areolar complex tattooing performed by a non-medical person: A case report. *World J Clin Cases* 2022; 10(34): 12781-12786

URL: <https://www.wjgnet.com/2307-8960/full/v10/i34/12781.htm>

DOI: <https://dx.doi.org/10.12998/wjcc.v10.i34.12781>

INTRODUCTION

The nipple areolar complex (NAC) is an important landmark in the breast and has a cosmetic significance[1]. Therefore, it is important to preserve the NAC as much as possible during surgeries, such as mastopexy, mastectomy, and breast reconstruction. If the NAC is damaged, it is necessary to restore its shape and color[2]. NAC tattooing is a procedure that can restore the color of the abnormal NAC and make it look more natural. Tattooing is usually performed by using a tattoo machine to insert ink into the dermal layer at a certain depth with a fine needle[3,4]. In South Korea, a tattoo is defined as an invasive procedure in humans; thus, only doctors can legally perform a tattoo. Therefore, tattoos administered by unlicensed non-medical personnel are illegal in South Korea[5]. Nonetheless, illegal tattoo procedures by non-medical personnel are increasing[6]. This is because the overall demand for tattoos has increased compared to the past, and it has become more accessible to the general public[7]. In addition, the purpose of tattoos has expanded in various ways; thus, tattoos are used for permanent makeup, such as eyebrows, eyeliner, and hairline. The perception of tattoos is also changing positively [8].

As mentioned earlier, tattoo procedures performed by non-medical personnel are illegal in Korea and Japan[5]. Also, some countries in Islamic culture do not allow tattoos[9]. Denmark does not allow tattoos on the face, neck, or hands[10]. There are regulations on tattoos in many other countries[11]. In common, most countries restrict unsanitary and illegal ink and tattoo procedures because of the possibility of infection or various side effects[12-15].

The author intends to report the harm and risk of non-medical tattoo procedures by presenting the case a patient who illegally received tattoo procedures from non-medical personnel without a license.

CASE PRESENTATION

Chief complaints

A 28-year-old woman visited the emergency room with pain, swelling, and exudation of both nipples after receiving a tattoo on her areolar area.

History of present illness

Pain and inflammation that occurred after receiving the tattoo three days ago worsened over time; hence, the patient visited our hospital.

History of past illness

The patient had a medical history of breast reduction and NAC reduction 10 years ago. She received a tattoo on both areolas due to dissatisfaction with the NAC color. The patient said she had been given a tattoo by an unlicensed person at an illegal tattoo clinic. The patient showed that both sides of the areolar area were stained with orange color ink.

Personal and family history

The patient denied any family history of similar symptoms.

Physical examination

The type of ink used in the tattoo could not be determined, and the method used for the procedure was not known. Pinpoint bleeding was found in both areolar areas, and the exudate mixed with pus and orange color ink were discharged. The size of both NACs appeared asymmetric. The nipples remained dark brown in color because tattoos were not performed on the nipples, and they did not match the color of the areolar area (Figures 1 and 2).

Laboratory examinations

The patient refused any laboratory examinations or clinical study.

Imaging examinations

The patient has not undergone an imaging examination.

FINAL DIAGNOSIS

The final diagnoses were cellulitis, allergic dermatitis, and foreign body reactions in the NAC.

TREATMENT

Because the patient did not have medical insurance, she refused any examination or hospitalization, and instead received outpatient treatment. Therefore, bacterial culture tests, blood tests, and biopsy were not performed. In order to control inflammation, cefroxadine antibiotic, a first-generation cephalosporin, was administered orally. Tulle dressing and foam dressing were applied to accelerate epithelialization and control exudation. Two weeks later, inflammation and exudation were controlled. Epithelialization progressed, and edema and pain decreased (Figure 3A). Four weeks later, the wound had completely healed. More than half of the orange ink in the areolar area was lost, and hyperpigmentation and hypopigmentation occurred partially. Asymmetry of both areolar sizes and color mismatch with nipples persisted (Figure 3B).

OUTCOME AND FOLLOW-UP

After the treatment was completed, NAC correction surgery and tattoo were required to correct asymmetry of the NACs, but the patient was lost to follow-up and contact.

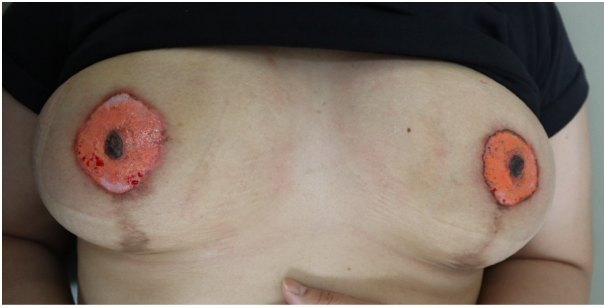DISCUSSION

It can be assumed that the reason for infection after the tattoo procedure was that the safety of ink used had not been assessed, the procedure itself was a septic procedure, or a problem occurred in the post-tattoo management stage. Since biopsy, blood test, or culture test was not performed, the exact cause could not be confirmed. Viruses[16], bacteria[17], and fungi[18,19] can cause infections after the tattoo procedure. As the number of tattoo procedures increase[5-7], various side effects due to infection are also increasing; thus, medical experts need to pay attention.

As non-infectious complications, itching and swelling are the most common, and they occur in 30% of people who have tattoos. Local reactions may include a papulo-nodular pattern, plaque-like pattern, excessive hyperkeratosis pattern, lymphopathic pattern, neurosensory pattern, and various side effects, such as general conditions, may occur[20]. Therefore, continuous and close management from a medical perspective is required even during and after tattoo procedures.

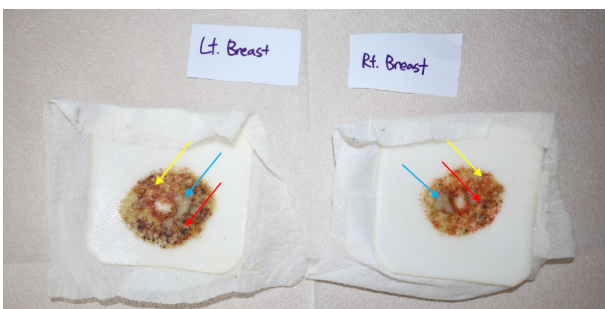
Illegal inks that have not been evaluated for human fitness are likely to contain unknown ingredients and have serious side effects. Mikkelsen *et al*[21] reported a case of exfoliative dermatitis that occurred after using a home kit tattoo ink purchased in China. The patient had serious side effects showing edema, redness, pus formation, and dry crustation all over the body. It was confirmed that our patient had been tattooed by a Chinese person, and similarly, the procedure was unsanitary with ink that could not be identified. Therefore, it is very important for public health workers to perform the tattoo procedure hygienically using ink approved by the Food and Drug Administration or a national institution.

In a study conducted in Germany based on public search terms for tattoos, the search terms for tattoo bump, raised tattoo, swollen tattoo, itchy tattoo, tattoo fading increased sharply between 2014-2018 compared to 2004-2008, and also the search terms for infected tattoo and tattoo healing increased[22]. Among these search terms were conditions that may require medical management and treatment.



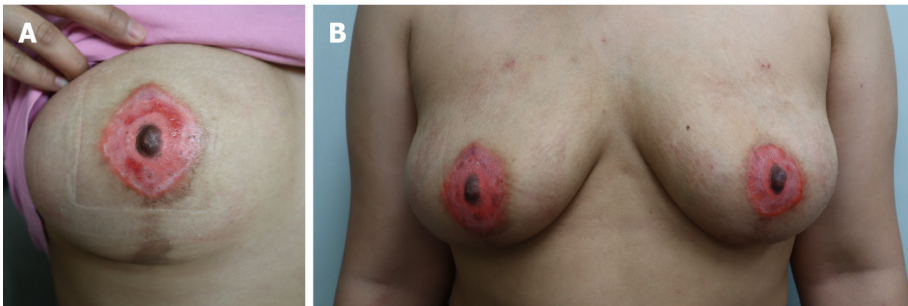
DOI: 10.12998/wjcc.v10.i34.12781 Copyright ©The Author(s) 2022.

Figure 1 Initial Photograph of both nipple areolar complex. Scars were seen on both peri-areolar areas and lower pole of the breast after the breast reduction operation. Pinpoint bleeding was found in both areolar areas. The size of the nipple areolar complex (NAC) on the right side appeared larger than that of the NAC on the left side. The nipples remained dark brown in color because tattoos were not performed on that area and they did not match the color of the areolar area. Hypopigmentation was seen in both areolar areas.



DOI: 10.12998/wjcc.v10.i34.12781 Copyright ©The Author(s) 2022.

Figure 2 An exudate from the areolar area. Red arrow indicated blood clot and bleeding. Yellow arrow indicated orange color ink ejected from the areolar area. Blue arrow indicated an exudate mixed with pus.



DOI: 10.12998/wjcc.v10.i34.12781 Copyright ©The Author(s) 2022.

Figure 3 A photograph taken after treatment. A: A photograph taken after two weeks of treatment. Swelling, discharge, and pain improved, and bleeding stopped. Epithelialization was in progress, but there was still a raw surface on the areolar area. Hyperpigmentation and hypopigmentation were seen. Also, color mismatch and size mismatch of both nipple areolar complex (NACs) were noted, and there was a color mismatch between the nipple and areolar area, which looked unnatural; B: A photograph taken after four weeks of treatment. After treatment, more than half of the ink was lost, leaving only a part. Hyperpigmentation and hypopigmentation had worsened. It was necessary to correct the size and color of both NACs. The areolar tissue had turned into scar tissue and looked even more unnatural.

Therefore, appropriate counseling and treatment should be provided based on a professional background to patients complaining of side effects of tattoos.

Recently, the scope of application of tattoos has expanded to a permanent makeup procedure, and in this case, tattoos have been used for cosmetic purposes of the NAC. Tattoos are being increasingly used to cover up scars or complexes. Like Korea, Japan also restricts tattoo procedures to doctors and nurses with medical licenses. Tomita *et al*[5] reported the experience of tattoo procedures by medical personnel. In 1352 patients, the rate of overall side effects was 12%, which was lower than the usual rate of side effects; and among them, itching or swelling were the most common. The proportion of infection was very small, with only three cases, and the proportion of satisfaction was high. Therefore, profes-

sional background knowledge and procedures for tattooing are essential[23].

Like a permanent makeup tattoo, the NAC can show good results if properly planned and treated by medical personnel. Sowa *et al*[24] performed medical tattooing on the NAC. Compared to the traditional tattoo, more natural and satisfactory results were obtained through the 3D enhancing technique. Uhlmann *et al*[25] successfully reconstructed the NAC through a 3D areolar dermopigmentation technique. If our patient had been tattooed by utilizing the above techniques, better results could have been obtained. The process of removing tattoos involves high cost and time, and pain occurs[26]. Therefore, it is essential to plan adequately before getting a tattoo and to get a tattoo hygienically from an expert.

CONCLUSION

Tattoos have a positive meaning for many purposes. There are many possibilities in which tattoos can be used in the medical field. Even for getting cosmetic tattoos for non-medical purposes, a plastic surgeon with professional knowledge should be preferred compared to non-medical personnel. Careful planning, safe ink and legally approved ingredient, hygienic procedures, and systematic management should be performed so that side effects can be reduced and satisfaction can be increased in people.

FOOTNOTES

Author contributions: Byeon JY and Kim TH contributed to manuscript writing and editing, and data collection; Choi HJ contributed to conceptualization and supervision; all authors have read and approved the final manuscript.

Informed consent statement: Written informed consent was obtained from the patient for publication of this report and any accompanying images.

Conflict-of-interest statement: All the authors report no relevant conflicts of interest for this article.

CARE Checklist (2016) statement: The authors have read the CARE Checklist (2016), and the manuscript was prepared and revised according to the CARE Checklist (2016).

Open-Access: This article is an open-access article that was selected by an in-house editor and fully peer-reviewed by external reviewers. It is distributed in accordance with the Creative Commons Attribution NonCommercial (CC BY-NC 4.0) license, which permits others to distribute, remix, adapt, build upon this work non-commercially, and license their derivative works on different terms, provided the original work is properly cited and the use is non-commercial. See: <https://creativecommons.org/licenses/by-nc/4.0/>

Country/Territory of origin: South Korea

ORCID number: Je Yeon Byeon 0000-0002-1948-0687; Hwan-Jun Choi 0000-0002-0752-0389.

S-Editor: Fan JR

L-Editor: A

P-Editor: Fan JR

REFERENCES

- 1 **Nicholson BT**, Harvey JA, Cohen MA. Nipple-areolar complex: normal anatomy and benign and malignant processes. *Radiographics* 2009; **29**: 509-523 [PMID: 19325062 DOI: 10.1148/rg.292085128]
- 2 **Egan KG**, Cullom M, Nazir N, Butterworth JA. Patient Satisfaction Increases with Nipple Reconstruction following Autologous Breast Reconstruction. *Plast Reconstr Surg* 2021; **148**: 177e-184e [PMID: 34133405 DOI: 10.1097/PRS.00000000000008390]
- 3 **Ruffolo AM**, Bruce WJ, Daugherty THF, Lee J, Sommer NZ. Technical Refinement in Three-Dimensional Nipple-Areola Complex Tattooing of the Reconstructed Breast. *Plast Reconstr Surg* 2021; **148**: 737-746 [PMID: 34550927 DOI: 10.1097/PRS.00000000000008390]
- 4 **Kuruvilla AS**, Gopman JM, Cham S, Henderson PW. Nipple-areolar tattoo: Comprehensive review of history, theory, technique, and outcomes. *J Plast Reconstr Aesthet Surg* 2022; **75**: 544-549 [PMID: 34728157 DOI: 10.1016/j.bjps.2021.09.024]
- 5 **Tomita S**, Mori K, Yamazaki H. Complications of permanent makeup procedures for the eyebrow and eyeliner. *Medicine (Baltimore)* 2021; **100**: e25755 [PMID: 33950961 DOI: 10.1097/MD.00000000000025755]
- 6 **Lee SH**, Lee CH, Kim JS, Park MY, Jeong CW, Lee SJ, Choi EH. Perception of Tattoos in South Korea: Analysis of Citizen Survey Data. *Korean J Dermatol* 2021; **15**: 24 [DOI: 10.13029/jkaps.2003.9.1.45]

- 7 **Kim YM**, Geum KS. A Study on the Reception and Spread of Tattoo Fashion. *J Korean Socie Costume* 2016; **66**: 18-31 [DOI: [10.7233/jksc.2016.66.3.018](https://doi.org/10.7233/jksc.2016.66.3.018)]
- 8 **Park J**. Signs of social change on the bodies of youth: tattoos in Korea. *Visual Commu* 2016; **15**: 71-92 [DOI: [10.1177/1470357215608552](https://doi.org/10.1177/1470357215608552)]
- 9 **Atik D**, Yildirim C. Motivations behind acquiring tattoos and feelings of regret: Highlights from an Eastern Mediterranean context. *J Consumer Behaviour* 2014; **13**: 212-223 [DOI: [10.1002/cb.1480](https://doi.org/10.1002/cb.1480)]
- 10 **European Council**. Resolution ResAP(2008)1 on requirements an criteria for the safety of tattoos and permanent make-up. In: Products CoEoC, ed; 2008
- 11 **Laumann AE**, Derick AJ. Tattoos and body piercings in the United States: a national data set. *J Am Acad Dermatol* 2006; **55**: 413-421 [PMID: [16908345](https://pubmed.ncbi.nlm.nih.gov/16908345/) DOI: [10.1016/j.jaad.2006.03.026](https://doi.org/10.1016/j.jaad.2006.03.026)]
- 12 **Sagoe D**, Pallesen S, Andreassen CS. Prevalence and correlates of tattooing in Norway: A large-scale cross-sectional study. *Scand J Psychol* 2017; **58**: 562-570 [PMID: [29105125](https://pubmed.ncbi.nlm.nih.gov/29105125/) DOI: [10.1111/sjop.12399](https://doi.org/10.1111/sjop.12399)]
- 13 **Das Eidgenössische Departement des Innern (EDI)**. Verordnung über Gegenstände für den Schleimhaut-, Haut- und Haarkontakt sowie über Kerzen, Streichhölzer, Feuerzeuge und Scherzartikel (Verordnung über Gegenstände für den Humankontakt), Swiss Government. Bern, 2005: 1-26
- 14 **European Council**. Council directive 76/768/EEC on the approximation of the law as of the member states relating to cosmetic products. OJEU, 1976: 1-169
- 15 **Worp J**, Boonstra A, Coutinho RA, van den Hoek JA. Tattooing, permanent makeup and piercing in Amsterdam; guidelines, legislation and monitoring. *Euro Surveill* 2006; **11**: 34-36 [PMID: [16484732](https://pubmed.ncbi.nlm.nih.gov/16484732/) DOI: [10.2807/esm.11.01.00591-en](https://doi.org/10.2807/esm.11.01.00591-en)]
- 16 **Cohen PR**. Tattoo-Associated Viral Infections: A Review. *Clin Cosmet Investig Dermatol* 2021; **14**: 1529-1540 [PMID: [34720594](https://pubmed.ncbi.nlm.nih.gov/34720594/) DOI: [10.2147/CCID.S284796](https://doi.org/10.2147/CCID.S284796)]
- 17 **Dieckmann R**, Boone I, Brockmann SO, Hammerl JA, Kolb-Mäurer A, Goebeler M, Luch A, Al Dahouk S. The Risk of Bacterial Infection After Tattooing. *Dtsch Arztebl Int* 2016; **113**: 665-671 [PMID: [27788747](https://pubmed.ncbi.nlm.nih.gov/27788747/) DOI: [10.3238/arztebl.2016.0665](https://doi.org/10.3238/arztebl.2016.0665)]
- 18 **Park AM**, Hathaway NE, Wright KT. Mycobacterium mageritense tattoo infection: a known complication with a novel species. *Dermatol Online J* 2020; **26** [PMID: [32621684](https://pubmed.ncbi.nlm.nih.gov/32621684/)]
- 19 **Lobo Y**, Lun K. Tattoo-Associated Cutaneous *Mycobacterium mageritense* Infection: A Case Report and Brief Review of the Literature. *Case Rep Dermatol* 2021; **13**: 513-520 [PMID: [35082611](https://pubmed.ncbi.nlm.nih.gov/35082611/) DOI: [10.1159/000520255](https://doi.org/10.1159/000520255)]
- 20 **Serup J**, Carlsen KH, Sepehri M. Tattoo complaints and complications: diagnosis and clinical spectrum. *Curr Probl Dermatol* 2015; **48**: 48-60 [PMID: [25833625](https://pubmed.ncbi.nlm.nih.gov/25833625/) DOI: [10.1159/000369645](https://doi.org/10.1159/000369645)]
- 21 **Mikkelsen CS**, Holmgren HR, Arvesen KB, Jarjis RD, Gunnarsson GL. Severe scratcher-reaction: an unknown health hazard? *Dermatol Reports* 2015; **7**: 5816 [PMID: [25918618](https://pubmed.ncbi.nlm.nih.gov/25918618/) DOI: [10.4081/dr.2015.5816](https://doi.org/10.4081/dr.2015.5816)]
- 22 **Kluger N**. Tattoo side effects worldwide: a Google Trends-based time series analysis. *Acta Dermatovenerol Alp Pannonica Adriat* 2019; **28**: 125-127 [PMID: [31545390](https://pubmed.ncbi.nlm.nih.gov/31545390/)]
- 23 **Rubio L**, Costa M, Barrulas P, Lores M, Garcia-Jares C, Barrocas-Dias C. Understanding the chemical and mineralogical composition of commercial henna and jagua tattoos and dyes-a multi-analytical approach. *Anal Bioanal Chem* 2022; **414**: 6233-6246 [PMID: [35829771](https://pubmed.ncbi.nlm.nih.gov/35829771/) DOI: [10.1007/s00216-022-04194-1](https://doi.org/10.1007/s00216-022-04194-1)]
- 24 **Sowa Y**, Kodama T, Hori T, Numajiri T. A Medical Tattooing Technique for Enhancing the Three-Dimensional Appearance of the Nipple-Areola Complex After Flap-Based Nipple Reconstruction. *Aesthetic Plast Surg* 2021; **45**: 2631-2636 [PMID: [34350501](https://pubmed.ncbi.nlm.nih.gov/34350501/) DOI: [10.1007/s00266-021-02471-5](https://doi.org/10.1007/s00266-021-02471-5)]
- 25 **Uhlmann NR**, Martins MM, Piato S. 3D areola dermopigmentation (nipple-areola complex). *Breast J* 2019; **25**: 1214-1221 [PMID: [31321852](https://pubmed.ncbi.nlm.nih.gov/31321852/) DOI: [10.1111/tbj.13427](https://doi.org/10.1111/tbj.13427)]
- 26 **Khunger N**, Molpariya A, Khunger A. Complications of Tattoos and Tattoo Removal: Stop and Think Before you ink. *J Cutan Aesthet Surg* 2015; **8**: 30-36 [PMID: [25949020](https://pubmed.ncbi.nlm.nih.gov/25949020/) DOI: [10.4103/0974-2077.155072](https://doi.org/10.4103/0974-2077.155072)]



Published by **Baishideng Publishing Group Inc**
7041 Koll Center Parkway, Suite 160, Pleasanton, CA 94566, USA
Telephone: +1-925-3991568
E-mail: bpgoffice@wjgnet.com
Help Desk: <https://www.f6publishing.com/helpdesk>
<https://www.wjgnet.com>

