

CASE REPORT

Meigs' Syndrome with Elevated Cancer Antigen 125

Hye-Na Park, Sun-Gyoeng Kim, Yun-Sook Kim

Department of Obstetrics and Gynecology, Soonchunhyang University Cheonan Hospital, Soonchunhyang University College of Medicine, Cheonan, Korea

Meigs' syndrome is a fibroma associated with ascites and/or pleural effusion and several cases have been reported in association with elevated serum cancer antigen (CA) 125 level. We report here on a 72-year-old woman who presented with palpable huge pelvic mass. Abdomen and pelvic computed tomography showed a heterogenous huge pelvic mass measuring 210×110 mm with large amount of ascites. No pleural effusion was detected on chest X-ray. CA 125 level was 327 IU/mL. The patient underwent laparotomy during which a mass measuring 210×110 mm was detected in her right ovary with 1,000 mL of ascites. Histology showed ovarian fibroma. We performed total abdominal hysterectomy with bilateral salpingo-oophorectomy. Postmenopausal woman with ovarian tumor, ascites, and elevated CA 125 may indicate malignant ovarian tumor, but Meigs' syndrome must be considered as differential diagnosis.

Keywords: Meigs' syndrome; Fibroma; Ascites; CA-125 antigen

INTRODUCTION

Ovarian cancer is the second most common gynecologic malignancy and the most common cause of gynecologic cancer death in the United States. The majority of ovarian malignancies are derived from epithelial cells [1]. The remainders arise from other ovarian cell types like as germ cell tumors and sex cord-stromal tumors. Clinical presentations of ovarian cancer include palpable pelvic mass, pelvic and abdominal symptoms such as abdominal bloating, distension, urinary urgency, dyspnea, and pelvic pain. Postmenopausal woman with adnexal mass, ascites, and elevated cancer antigen (CA) 125 may indicate ovarian cancer. But Meigs' syndrome must be considered as differential diagnosis. Meigs' syndrome is a benign disease that disappears after removal of the pelvic mass [2]. We report on a case of Meigs' syndrome caused by right ovarian fibroma with elevated serum CA 125 level in a postmenopausal woman.

CASE REPORT

A 72-year-old Korean woman visited to Soonchunhyang Uni-

versity Cheonan Hospital because of progressive abdominal distention. Her obstetric history included two uncomplicated vaginal deliveries and menopause occurred at the age of 50 years. She had previously been in good health with no medical history and had no specific familial medical history.

On physical examination, the patient had a body weight of 74 kg, a blood pressure of 150/100 mm Hg, a pulse rate of 110 beats/min, a respiratory rate of 20 breaths/min, and a normal body temperature. Her abdomen was distended with dullness in percussion and a positive shifting dullness. On gynecological exam, a large pelvic mass was palpated in the right adnexa. Pelvic ultrasonography showed a solid mass measuring 210×110 mm in the entire pelvic area with ascites (Fig. 1). The contrast enhanced abdomen and pelvic computed tomography scan showed huge solid heterogenous mass and large amount of ascites (Fig. 2).

The patient showed hemoglobin was 10.3 g/dL (range, 12.0 to 16.0 g/dL), white blood cell $14.5 \times 10^3/\mu\text{L}$ (range, 4.0 to $10.8 \times 10^3/\mu\text{L}$), and platelet $261/\text{mm}^3$ (range, 130 to $400/\text{mm}^3$). Serum biochemistry and coagulation profiles were within normal limits. The patient was negative for hepatitis B, syphilis, and human immunodeficiency viruses. CA 125 level was 327 IU/mL (range, 0 to 35 IU/

Correspondence to: Yun-Sook Kim

Department of Obstetrics and Gynecology, Soonchunhyang University Cheonan Hospital, Soonchunhyang University College of Medicine, 31 Suncheonhyang 6-gil, Dongnam-gu, Cheonan 31151, Korea

Tel: +82-41-570-2150, Fax: +82-41-571-7887, E-mail: drsook@schmc.ac.kr

Received: May 7, 2016 / Accepted after revision: Sep. 6, 2016

© 2016 Soonchunhyang Medical Research Institute

This is an Open Access article distributed under the terms of the Creative Commons Attribution Non-Commercial License (<http://creativecommons.org/licenses/by-nc/4.0/>).

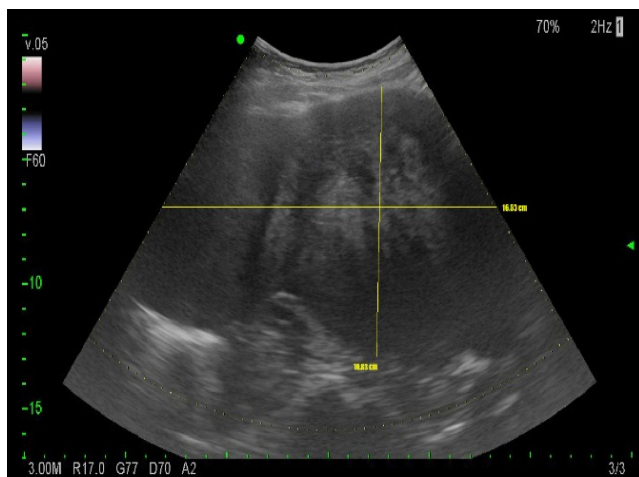


Fig. 1. The ultrasonography revealed huge heterogenous pelvic mass.

mL) and other tumor markers were within the normal range.

We suspected on malignancy potential of pelvic mass, and a patient underwent explorative laparotomy. During surgery, a right adnexal solid mass measuring 210 × 110 mm without excrescences and without ruptured material was founded. Pelvic ascites (1,000 mL) was discovered and aspiration cytology was done. The uterus and left adnexa were normal. Frozen section of the mass was reported as benign ovarian fibroma. The bowels and omentums were grossly free of disease. Postoperative histology confirmed benign fibroma of the right ovary. After surgery, we checked CA 125 level on third postoperative day and it was decreased to 235 IU/mL. All symptoms were disappeared and the patient was discharged on the fifth postoperative day. She was very healthy on three months after discharge, and the level of CA 125 was normalized.

DISCUSSION

In 1934, Salmon described the association of pleural effusion with benign pelvic tumors [1]. It was not until the report by Meigs and Cass [3] in 1937 that widespread attention of the medical profession was drawn to the significance of pleural effusion and ascites in benign ovarian fibroma. Ovarian fibroma is found in 2% to 5% of surgically removed ovarian tumors, and Meigs' syndrome is observed in about 1%. Ascites is present in 10% to 15% of those with ovarian fibroma and pleural effusion in 1%, especially with large lesion. Fibromas are the most common of the sex cord-stromal tumors which are benign solid neoplasms, usually unilateral, that primarily occur in postmenopausal women [4]. On ultra-

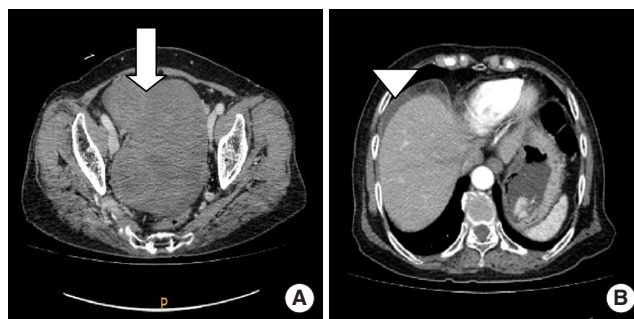


Fig. 2. (A, B) The contrast-enhanced abdomen and pelvic computed tomography scan showed solid large pelvic mass (arrow) and ascites (arrow head).

sound examination, an ovarian fibroma may appear as a mass that is either hyperechoic or hypoechoic, which may be calcified or exhibit cystic degeneration. Like our case, it can be looked heterogenous. Ascites is present in 10% to 15% of cases and hydrothorax in 1%, especially with larger lesions [5]. Meigs' syndrome includes a pelvic mass or benign ovarian tumor, ascites with or without pleural effusion, which all disappear after tumor removal [6]. Fluid accumulation is probably related to substances like vascular endothelial growth factor that raise capillary permeability [7]. Pseudo-Meigs' syndrome is a clinical syndrome of pleural effusion, ascites, and an ovarian mass that is not a fibroma or fibroma-like mass has been reported from a number of sources, such as leiomyomas, struma ovarii, mucinous cystadenoma, teratoma, and malignancies that are metastatic to the ovary like as colorectal cancer [8,9]. The most common treatment for an ovarian fibroma is unilateral salpingo-oophorectomy. For women who desire preservation of the ovary, an ovarian cystectomy may be performed with complete excision of the fibromatous tissue by laparotomy or laparoscopy [10]. The key diagnostic differential is to distinguish the low malignancy potential fibroma from the aggressive malignancy of ovarian fibrosarcoma [11]. So we performed total hysterectomy with bilateral salpingo-oophorectomy. Postmenopausal women with clinical symptom of palpable pelvic masses, ascites, pleural effusion, and elevated serum CA 125 levels probably have possibility of malignant ovarian tumors. However, Meigs' syndrome also has to be the differential diagnosis in this situation.

REFERENCES

1. Parkin DM, Bray F, Ferlay J, Pisani P. Global cancer statistics, 2002. *CA Cancer J Clin* 2005;55:74-108.
2. Park JW, Bae JW. Postmenopausal Meigs' syndrome in elevated CA-125: a case report. *J Menopausal Med* 2015;21:56-9.

3. Meigs JV, Cass JW. Fibroma of the ovary with ascites and hydrothorax: with a report of seven cases. *Am J Obstet Gynecol* 1937;33:249-67.
4. Thirkell D, Taylor JH, Ingram CG. Meigs' syndrome: a case report. *J Coll Gen Pract* 1963;6:400-7.
5. Turan YH, Demirel LC, Ortac F. Elevated CA 125 in Meigs syndrome. *Int J Gynaecol Obstet* 1993;43:64-5.
6. Abramov Y, Anteby SO, Fasouliotis SJ, Barak V. The role of inflammatory cytokines in Meigs' syndrome. *Obstet Gynecol* 2002;99(5 Pt 2):917-9.
7. Benjapibal M, Sangkarat S, Laiwejpithaya S, Viriyapak B, Chaopotong P, Jaishuen A. Meigs' syndrome with elevated serum CA125: case report and review of the literature. *Case Rep Oncol* 2009;2:61-6.
8. Mostaghel N, Enzevaei A, Zare K, Fallahian M. Struma ovarii associated with pseudo-Meigs' syndrome and high serum level of CA 125: a case report. *J Ovarian Res* 2012;5:10.
9. Maeda H, Okabayashi T, Hanazaki K, Kobayashi M. Clinical experience of pseudo-Meigs' syndrome due to colon cancer. *World J Gastroenterol* 2011;17:3263-6.
10. Maccio A, Madeddu C, Kotsonis P, Pietrangeli M, Paoletti AM. Large twisted ovarian fibroma associated with Meigs' syndrome, abdominal pain and severe anemia treated by laparoscopic surgery. *BMC Surg* 2014;14:38.
11. Prat J, Scully RE. Cellular fibromas and fibrosarcomas of the ovary: a comparative clinicopathologic analysis of seventeen cases. *Cancer* 1981; 47:2663-70.