

CASE REPORT

Prevotella bivia Infection Following Supracervical Hysterectomy: Case Report with a Review of Literatures

Sang-Min Shim, Yun-Sook Kim

Department of Obstetrics and Gynecology, Soonchunhyang University Cheonan Hospital, Soonchunhyang University College of Medicine, Cheonan, Korea

Prevotella bivia (*P. bivia*) has a high proliferative potential in the presence of estrogen. Therefore, its involvement in vaginal tract infections, such as endometritis and pelvic inflammatory disease, has been well described in the literature. We experienced a very rare case of a 40-year old woman with a 6-cm abscess on the cuff who presented with a large amount of vaginal discharge and nausea two months after laparoscopic supracervical hysterectomy. Our case indicates that clinicians should be aware of the possibility of *P. bivia* infections although rare.

Keywords: *Prevotella bivia*; Abscess; Supracervical hysterectomy

INTRODUCTION

Prevotella bivia (*P. bivia*) is an anaerobic, non-pigmented, gram-negative bacillus which is naturally present in the human female vaginal tract, and it is also occasionally seen in the oral cavity [1,2]. It has a high proliferative potential in the presence of estrogen. Therefore, its involvement in, vaginal tract infections such as endometritis and pelvic inflammatory disease, has been well described in the literature [3,4]. If left untreated, it may cause more serious conditions, such as cuff abscess, abdominal wall empyema, or septic arthritis [5,6]. We experienced a very rare case of a 40-year-old woman with a 6-cm abscess on the cuff who presented with a large amount vaginal discharge and nausea two months after laparoscopic supracervical hysterectomy. We report rare case with a brief review of literatures.

CASE REPORT

A 40-year-old woman visited emergency clinic of Soonchunhyang University Cheonan Hospital with a chief complaint of 2-week-history of a large amount of yellow and foul odorous vaginal discharge and nausea. The patient also had a fishy vaginal odor in the

cervix, which was noticeable following sexual intercourse. The patient had a parity of 2-0-0-2 and a divorced state. In addition, the patient had no notable findings on family and past medical history. Furthermore, the patient also had a 2-month-history of taking supracervical hysterectomy for huge myoma. Preoperatively, the patient had normal Pap smear and very good conditions, except for which the patient had a 5-year-history of undergoing insertion of copper 386 loop. The patient underwent uneventful course without bleeding. Postoperatively, the abdominal cavity was very clear on pelviscopy (Fig. 1). On pelvic ultrasonography, the patient had normal cuff and bilateral ovaries one month postoperatively (Fig. 2A).

On physical examination and serum biochemistry, the patient had a temperature of 36.7°C, and serum C-reactive protein levels of 1.0 mg/L (normal range, 0.01-3.0 mg/L). The patient had a 61×53 mm abscess on the cuff on transvaginal ultrasonography (Fig. 2B), for which we administered oral antibiotics such as doxycycline and metronidazole. On bacterial culture test with vaginal discharge at that day, gram negative *P. bivia* was identified. Therefore, the patient was treated with a 14-day course of aerobic specific antibiotics such as cefoxitin plus metronidazole plus doxycycline. One day 14, the size of the abscess on the cuff was decreased to 45×30 mm.

Correspondence to: Yun-Sook Kim

Department of Obstetrics and Gynecology, Soonchunhyang University Cheonan Hospital, Soonchunhyang University College of Medicine, 31 Suncheonhyang 6-gil, Dongnam-gu, Cheonan 330-930, Korea

Tel: +82-41-570-2150, Fax: +82-41-571-7887, E-mail: drsook@schmc.ac.kr

Received: Sep. 28, 2014 / Accepted after revision: Oct. 8, 2014

© 2014 Soonchunhyang Medical Research Institute

This is an Open Access article distributed under the terms of the Creative Commons Attribution Non-Commercial License (<http://creativecommons.org/licenses/by-nc/3.0/>).

Two months thereafter, the patient achieved a complete resolution of the abscess on the cuff without recurrent episodes. In addition, at 12-month follow-up, the patient had no notable findings or recurrences.

DISCUSSION

The DNA of *P. bivia* has been detected from human vaginal epithelia in 40% of healthy women. The prevalence is relatively higher in women with bacterial vaginosis (BV) [7]. Its detection from the glans penis indicates that it is a causative factor of BV in female sex partners [8]. It is also probable, however, that traumatic events such as human bite might cause *P. bivia* infections leading to suppurative

inguinal adenitis during orogenital sex. It is also a normal oral and vaginal flora as well as a predominant type of bacillus isolated from the respiratory tract infections and their complications, including aspiration pneumonia, lung abscess, chronic otitis media, chronic sinusitis, abscesses in the oral cavity, human bites, brain abscesses, and osteomyelitis. Moreover, *P. bivia* is the important pathogen in obstetric and gynecologic infections.

P. bivia is present in the digestive tract extending from the oral cavity to the anus [9]. It is considered a common causative agent for infections secondary to animal and human bites. Human and animal bites usually contain polymicrobial, anaerobes that are isolated from more than 2/3 of human and animal bite wound infections, particularly including those associated with abscess formation [10]. There are reports about isolation from the blood of patients delivered by cesarean section as well as those with acute pelvic inflammatory diseases. It has been reported to invade the human cervix and to cause intrauterine infections. It is therefore considered a risk factor of aggravating pregnancy outcomes and fetus development. There is a report suggesting that the concentrations of *P. bivia* and lipopolysaccharide in the vaginal fluid may contribute to the severity of BV and to the development of adverse pregnancy outcomes, such as preterm labor, premature rupture of membranes, postpartum endometritis, and postoperative pelvic infection [11,12]. In our case, *P. bivia* in the vagina invade the cervix and caused the postoperative abscess on the cuff. In women with *P. bivia* undergoing hysterectomy, perioperative treatment with metronidazole elimi-

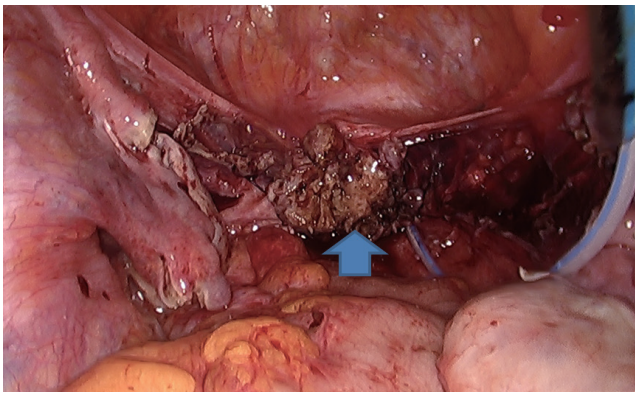


Fig. 1. Postoperatively, the abdominal cavity and the vault (arrow) were very clear on pelviscopy.

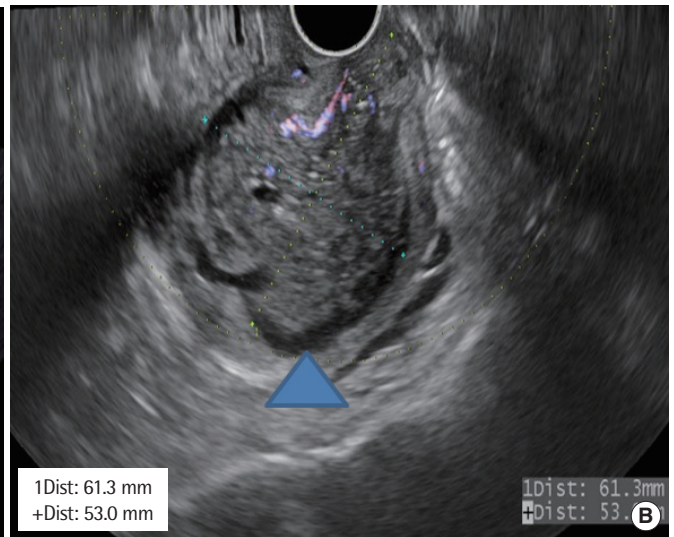
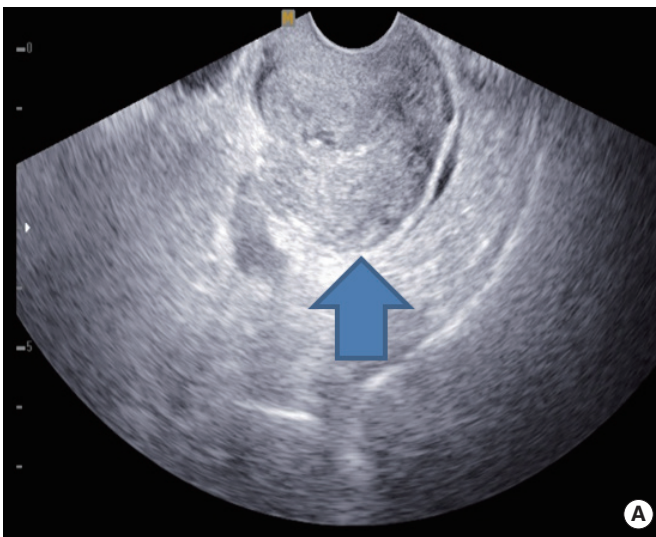


Fig. 2. The patient had a normal cuff (arrow) one month postoperatively (A), but a 61 × 53 mm abscess (arrow head) on the cuff two months after laparoscopic supra-cervical hysterectomy on transvaginal ultrasonography.

nates the risk of postoperative cuff infections after hysterectomy [13,14]. In Korea, however, clinicians are not allowed to use the first and second generation cephalosporins for the antimicrobial prophylaxis from immediately before skin incision to postoperative day 1. We could not use additional antibiotics to the patient has no sign of infections.

Our case indicates that clinicians should be aware of possibility of *P. bivia* infections although rare. And neurologic complications like as brachial plexus injury are rarely associated with laparoscopic procedures [15].

In addition, clinicians should collect anerobic cultures from patients with history of contact to infection sites currently with mucosal damages. Good clinical outcomes are predicted from patients with is positive anerobic gram-negative rods, if they are treated with aerobic specific antibiotics in a timely manner.

ACKNOWLEDGMENTS

This work was supported in part by the Soonchunhyang University Research Fund.

REFERENCES

1. Riesbeck K. Paronychia due to *Prevotella bivia* that resulted in amputation: fast and correct bacteriological diagnosis is crucial. *J Clin Microbiol* 2003; 41:4901-3.
2. Hsu GJ, Chen CR, Lai MC, Luh SP. Chest wall abscess due to *Prevotella bivia*. *J Zhejiang Univ Sci B* 2009;10:233-6.
3. Laiho K, Kotilainen P. Septic arthritis due to *Prevotella bivia* after intra-articular hip joint injection. *Joint Bone Spine* 2001;68:443-4.
4. Purushothaman B, Lakshmanan P, Gatehouse S, Fender D. Spondylodiscitis due to *Prevotella* associated with ovarian mass: a rare case report and review of literature. *World Neurosurg* 2010;73:119-22.
5. Salman SA, Baharoon SA. Septic arthritis of the knee joint secondary to *Prevotella bivia*. *Saudi Med J* 2009;30:426-8.
6. Mirza A, Bove JJ, Litwa J, Appelbe G. Mixed Infections of the Paronychium with *Prevotella bivia*. *J Hand Microsurg* 2012;4:77-80.
7. Srinivasan S, Fredricks DN. The human vaginal bacterial biota and bacterial vaginosis. *Interdiscip Perspect Infect Dis* 2008;2008:750479.
8. Price LB, Liu CM, Johnson KE, Aziz M, Lau MK, Bowers J, et al. The effects of circumcision on the penis microbiome. *PLoS One* 2010;5:e8422.
9. Alauzet C, Marchandin H, Lozniewski A. New insights into *Prevotella* diversity and medical microbiology. *Future Microbiol* 2010;5:1695-718.
10. Brook I. Microbiology and management of human and animal bite wound infections. *Prim Care* 2003;30:25-39, v.
11. Aroutcheva A, Ling Z, Faro S. *Prevotella bivia* as a source of lipopolysaccharide in the vagina. *Anaerobe* 2008;14:256-60.
12. Smayevsky J, Canigia LF, Lanza A, Bianchini H. Vaginal microflora associated with bacterial vaginosis in nonpregnant women: reliability of sialidase detection. *Infect Dis Obstet Gynecol* 2001;9:17-22.
13. Watts DH, Krohn MA, Hillier SL, Eschenbach DA. Bacterial vaginosis as a risk factor for post-cesarean endometritis. *Obstet Gynecol* 1990;75:52-8.
14. Larsson PG, Carlsson B. Does pre- and postoperative metronidazole treatment lower vaginal cuff infection rate after abdominal hysterectomy among women with bacterial vaginosis? *Infect Dis Obstet Gynecol* 2002;10:133-40.
15. Chung SH, Kim TH, Lee HH, Lee KH, Park HS. Brachial plexus injury during laparoscopic gynecologic surgery in postmenopausal women. *J Korean Soc Menopause* 2011;17:52-6.