

Feasibility study of endoscopic biliary drainage under direct peroral cholangioscopy by using an ultra-slim upper endoscope (with videos)




Authors

Jae Keun Park¹, Jong Ho Moon¹, Yun Nah Lee¹, Seok jung Jo¹, Moon Han Choi¹, Tae Hoon Lee², Sang-Woo Cha³, Young Deok Cho³, Sang-Heum Park²

Institutions

- 1 Digestive Disease Center and Research Institute, Department of Internal Medicine, SoonChunHyang University School of Medicine, Bucheon, Korea
- 2 Digestive Disease Center and Research Institute, Department of Internal Medicine, SoonChunHyang University School of Medicine, Cheonan, Korea
- 3 Digestive Disease Center and Research Institute, Department of Internal Medicine, SoonChunHyang University School of Medicine, Seoul, Korea

University Bucheon Hospital, 170 jomaru-ro, Wonmi-gu, Bucheon, 14584, Korea
 Fax: +82-32-621-5018
 jhmoon@schmc.ac.kr

submitted 25.2.2020

accepted after revision 30.12.2020

Bibliography

Endosc Int Open 2021; 09: E1447–E1452

DOI 10.1055/a-1522-5615

ISSN 2364-3722

© 2021. The Author(s).

This is an open access article published by Thieme under the terms of the Creative Commons Attribution-NonDerivative-NonCommercial License, permitting copying and reproduction so long as the original work is given appropriate credit. Contents may not be used for commercial purposes, or adapted, remixed, transformed or built upon. (<https://creativecommons.org/licenses/by-nc-nd/4.0/>)

Georg Thieme Verlag KG, Rüdigerstraße 14,
 70469 Stuttgart, Germany

Corresponding author

Jong Ho Moon, MD, PhD, Department of Internal Medicine, SoonChunHyang University School of Medicine, Digestive Disease Center and Research Institute, SoonChunHyang

ABSTRACT

The therapeutic utility of peroral cholangioscopy (POC) is limited. Direct POC using an ultra-slim upper endoscope expands the therapeutic indications because of its larger working channel, of up to 2.2 mm. We evaluated the feasibility of selective biliary drainage using a plastic stent under direct POC. From April 2015 to March 2019, biliary drainage under endoscopic visualization was performed in the same endoscopic session as direct POC without exchanging the duodenoscope. After guidewire insertion through the stricture or stone, a 5 Fr plastic stent and/or nasobiliary drainage catheter was used for biliary drainage. Selective biliary drainage under direct POC was performed in 32 patients, including 17 with difficult bile duct stones. Biliary drainage was performed with a plastic stent in 29 patients, nasobiliary drainage in one, and combined drainage in two patients. The technical success rate for biliary drainage placement under direct POC was 100% (32/32). No significant procedure-related complications occurred. In conclusion, biliary drainage with a plastic stent or catheter under direct POC using an ultra-slim upper endoscope is feasible and may be useful for lesions obstructing the bile duct.

Introduction

Peroral cholangioscopy (POC) enables not only endoscopic direct visualization of the biliary system, but also interventions for diseases of the bile duct [1]. POC can be achieved using a conventional mother baby scope system, or the single operator cholangioscopy system with the SpyGlass Direct Visualization system or direct POC using an ultra-slim upper endoscope [1]. Selective guidewire access through complex strictures or

stones, and subsequent stent insertion under direct visualization, may increase the therapeutic utility of POC. However, mother-baby endoscope system and the SpyGlass direct visualization system have working channels of only 1.2 mm. Although selective guidewire advancement is possible, direct biliary stent placement is impossible using endoscopes with such small working channels. In contrast, direct POC using an ultra-slim upper endoscope with an up to 2.2-mm working channel ex-

pands the therapeutic indications for direct POC. We evaluated the feasibility of selective biliary drainage under direct POC.

Patients and methods

Patients and study design

This retrospective analysis of a prospectively maintained database study was performed in a single tertiary referral center from April 2015 to March 2019. The inclusion criteria were: (1) clinical symptoms of bile duct obstruction with jaundice; (2) diameter of the distal common bile duct (CBD) of ≥ 8 mm; (3) endoscopic sphincteroplasty and/or endoscopic papillary balloon dilation; and (4) need for direct POC. The exclusion criteria were: (1) age < 18 years; (2) contradictions for endoscopic retrograde cholangiopancreatography (ERCP); (3) bleeding tendency (platelet count of $< 50,000/\text{mm}^3$ or prothrombin time [PT] international normalised ratio [INR] of > 1.5); and (4) refusal to participate. Written informed consent for the endoscopic procedure was obtained from all of the enrolled patients. The Institutional Review Board of Soonchunhyang Medical Center approved the study protocol.

Instruments

The ultra-slim upper endoscopes were the GIF-XP260N, GIF-XP260NS, and GIF-XP290N instruments (Olympus Medical Systems, Co., Ltd., Tokyo, Japan), which have distal tips 5.0 to 5.5 mm in diameter. All of these endoscopes are forward-viewing type, featuring a 2.0- to 2.2-mm-diameter working channel and four-way deflection steering of the tip. A 5-Fr balloon catheter (MTW Endoskopie, Wesel, Germany) was used to assist the cholangioscopy [2]. For biliary drainage, 5-Fr plastic stents or nasobiliary drainage catheters were used (Cook Endoscopy, Winston-Salem, North Carolina, United States).

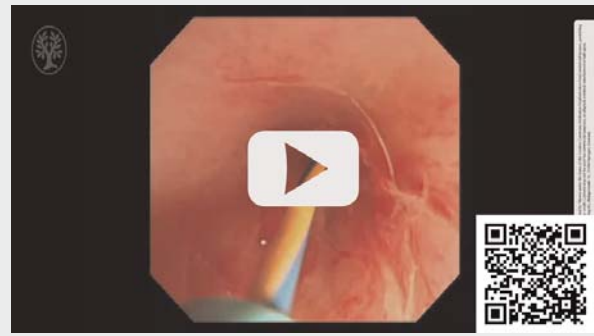
Direct POC procedure

The patients were placed in the prone position under sedation with midazolam and/or propofol and received prophylactic antibiotics. Endoscopic sphincterotomy and/or endoscopic papillary balloon dilatation was performed before the introduction of an ultra-slim endoscope for direct POC, which was performed using a previously described intraductal balloon-guided method [2,3]. Irrigation with sterile 0.9% NaCl and frequent suction were used to improve visualization during direct POC. Minimal insufflation of CO₂ (Colcosense CO-3000; Mirae Medicals, Co., Seoul, South Korea) was applied as needed, and room air insufflation was not used.

Biliary drainage procedure

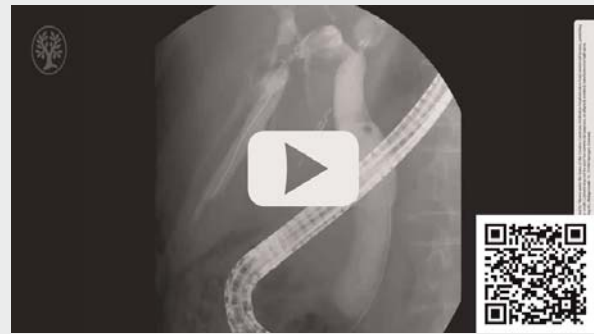A guidewire with a diameter of 0.025 or 0.035 inches was inserted under direct visualization through the stricture or stone. Biliary drainage was performed over the guidewire through the working channel of the ultra-slim upper endoscope using 5-Fr double-pigtail or straight plastic stent, and/or 5-Fr nasobiliary drainage catheters (► Fig. 1, ► Video 1, ► Video 2).

► VIDEO



► **Video 1** Endoscopic view of biliary drainage with a plastic stent for intrahepatic biliary stricture under direct peroral cholangioscopy using an ultra-slim upper endoscope.

► VIDEO



► **Video 2** Fluoroscopic view of biliary drainage with a plastic stent for intrahepatic biliary stricture under direct peroral cholangioscopy using an ultra-slim upper endoscope.

Definition of events and outcomes

Technical success was defined as successful endoscopic retrograde biliary drainage (ERBD) and/or endoscopic nasobiliary drainage (ENBD) placement in the bile duct under direct POC without exchange for a duodenoscope. Functional success was defined as resolution of clinical symptoms, including jaundice, after biliary drainage without any need for repeated drainage procedures. Adverse events (AEs) after ERCP were recorded according to the guidelines of the American Society for Gastrointestinal Endoscopy [4]. The primary outcome was the technical success rate. The secondary outcomes were the functional success rate and incidence of procedure-related AEs.

Statistical analysis

Demographic and clinical characteristics are presented as means (standard deviation) for continuous variables and frequencies (percentage) for categorical variables. Statistical analysis was performed using R (version 3.3.3; R Foundation for Sta-

► **Table 1** Baseline characteristics of the patients.

Characteristic	All patients (N=32)
Mean age ± SD, years	71.2 ± 11.3
Sex – number (%)	
▪ Male	16 (50)
▪ Female	16 (50)
Indications for direct POC – number (%)	
▪ Difficult CBD stones	17 (53.1)
▪ Evaluation of indeterminate BD lesion	12 (37.5)
▪ Tumor ablation therapy (PDT)	3 (9.4)

SD, standard deviation; POC, peroral cholangioscopy; CBD, common bile duct; BD, bile duct; PDT, photodynamic therapy.

► **Table 2** Summary of biliary drainage under direct POC.

	Number (%) (N=32)
Drainage under direct POC	
▪ ERBD	29 (91)
▪ ENBD + ENBD	2 (6)
▪ ENBD	1 (3)
Technical success	32 (100)
Functional success	32 (100)
Adverse events¹	1 (3.1)

POC, peroral cholangioscopy; ERBD, endoscopic retrograde biliary drainage; ENBD, endoscopic nasobiliary drainage.
¹ Minor bleeding.

tistical Computing, Vienna, Austria) or SPSS software (version 23.0; IBM Corp., Armonk, New York, United States).

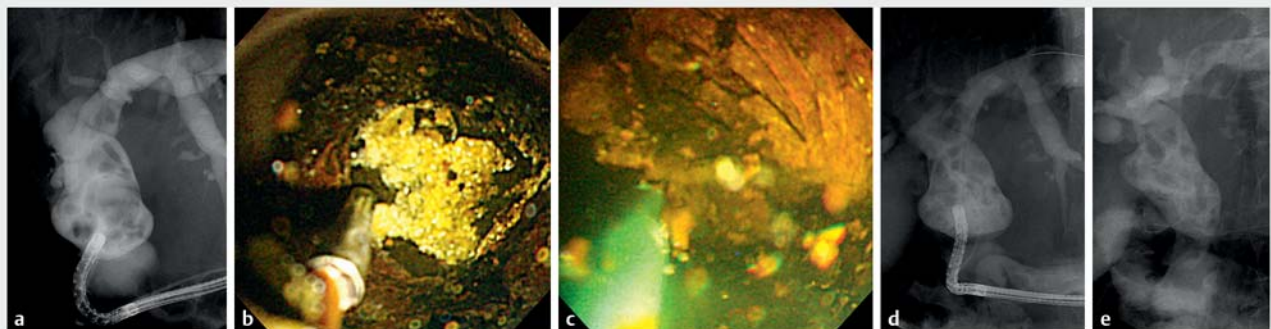
Results

Selective biliary drainage under direct POC using an ultra-slim upper endoscope was attempted in 32 patients (16 males, 16 females; mean age, 71.2 years). The baseline characteristics of the patients are listed in ► **Table 1**. The most common indication for direct POC was difficult bile duct stones (17 patients, 53.1%). Difficult bile duct stones were defined as larger than 15 mm and/or more than three stones that could not be removed despite an extended sphincterotomy and recurrent ERCP procedures may be needed [5, 6]. Biliary drainage was attempted after endoscopic intervention by direct POC guided intraductal electrohydraulic lithotripsy (EHL) (► **Fig. 1**), tumor ablation with photodynamic therapy (PDT) to check the exact extent and perform the procedure (► **Fig. 2**), and indeterminate biliary stricture in case of suspected malignant bile duct stricture, but failed diagnosis through conventional ERCP-guided tissue sampling (► **Fig. 3**).

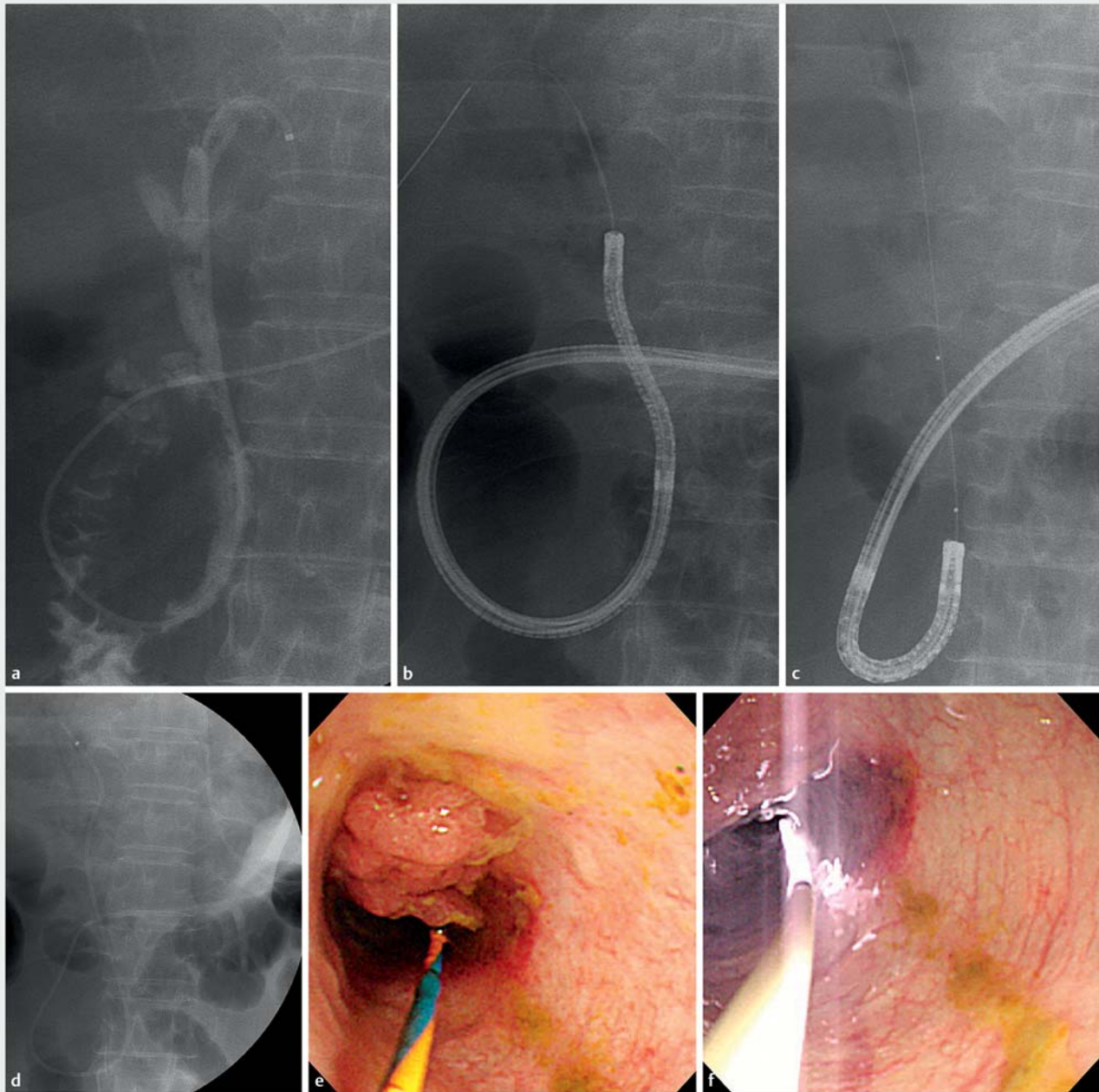
The technical success rate for selective biliary drainage under direct POC using an ultra-slim upper endoscope was 100%. Results of selective biliary drainage under direct POC are listed in ► **Table 2**. Twenty-nine patients (91%) underwent ERBD with 5-Fr plastic stents. One patient (3%) underwent only ENBD. ERBD and ENBD were performed simultaneously in two patients (6%). The functional success rate was 100% (32/32 patients). Only one patient had minor bleeding during the procedure after fragmentation of a stone by EHL.

Discussion

A variety of clinical conditions accompanied by jaundice necessitate biliary drainage. In cases of difficult guidewire placement, POC enables direct visualization of the lesion [7]. There have been several case reports of successful guidewire placement using the SpyGlass cholangioscope [8–10]. However, although SpyGlass cholangioscopy enables direct visualization of the bile duct, its therapeutic utility is limited by the small working channel (1.2 mm). Thus, the SpyGlass cholangioscope must be withdrawn before inserting the stent for drainage [11].



► **Fig. 1** **a** Cholangiogram of difficult bile duct stones. **b** Direct peroral cholangioscopy-guided intraductal electrohydraulic lithotripsy. **c** A 5-Fr plastic stent is inserted under direct peroral cholangioscopy (POC). **d** and **e** Fluoroscopic findings showing endoscopic retrograde biliary drainage (ERBD) under direct POC.

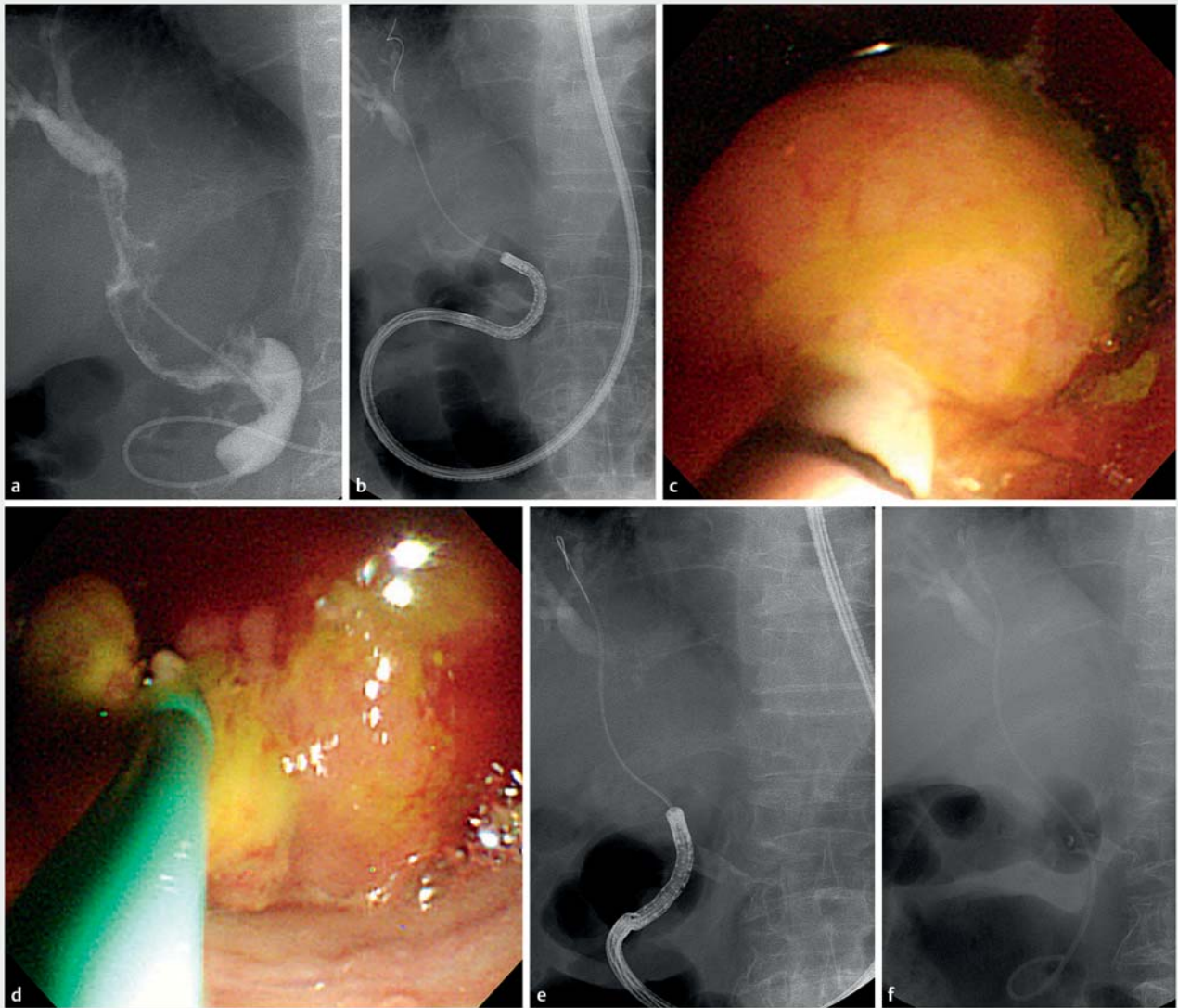


► **Fig. 2** **a** Cholangiogram of a luminal-obstructing mass lesion. **b** Fluoroscopic view showing the advancement of an ultra-slim endoscope using intraductal balloon-guided method. **c** Fluoroscopic view showing the advancement of a photodynamic therapy (PDT) catheter using an ultra-slim endoscope into the bile duct. **d** A 5-Fr endoscopic nasobiliary drainage was inserted under direct peroral cholangioscopy (POC). **e** Cholangioscopic view showing bile duct cancer. **f** Direct POC-guided PDT.

Single-operator direct POC using an ultra-slim upper endoscope has been proposed. Direct POC allows high-quality narrow-band imaging (NBI) and has a larger working channel (up to 2.2 mm in diameter) for interventional procedures [1, 2]. Thus, the limitations of cholangioscopy can be overcome by direct POC using a conventional ultra-slim upper endoscope. The 2.0-mm working channel of an ultra-slim endoscope enables direct placement of a 5 Fr diameter plastic stent or drainage tube, intraductal lithotripsy, intraductal ablation therapy for bile duct

tumors, and cholangioscopy-guided direct biliary drainage [1]. Direct POC also facilitates identification of the stricture site and direct drainage without changing the endoscope [7].

Our findings demonstrate the feasibility of selective biliary drainage under direct POC using an ultra-slim upper endoscope. The technical and functional success rates of biliary drainage were 100% in patients with a variety of clinical conditions, and minor bleeding after fragmentation of an intraductal stone by EHL was the only procedure-related AE. This indicates



► **Fig. 3** **a** Cholangiogram of indeterminate biliary stricture. **b** Fluoroscopic view showing the advancement of an ultra-slim endoscope into the bile duct and cannulation through the stricture. **c** Cholangioscopic view of intraductal mass. **d** A 5-Fr plastic stent was inserted under direct peroral cholangioscopy. **e** and **f** Fluoroscopic view showing selective cannulation and insertion of a 5-Fr plastic stent.

the safety of selective biliary drainage under direct POC using an ultra-slim upper endoscope, which also requires only minimal insufflation with CO₂ and administration of prophylactic antibiotics.

However, direct POC also has several limitations. First, direct POC can be performed only in patients with a dilated CBD (>8 mm). Major sphincterotomy and/or papillary balloon dilation are needed for smooth insertion of the ultra-slim endoscope into the biliary tree. Second, only 5 Fr plastic stents can be used due to the 2.0-mm working channel of the ultra-slim endoscope; therefore, >7-Fr conventional plastic stents cannot be used. In this study, direct POC was performed for the purpose of directly visualizing the extent of the lesion, biopsy, or PDT, especially in a malignant biliary stricture. Selective biliary drainage in this study was for biliary drainage to prevent devel-

opment of cholangitis. Third, although intraductal balloon-guided direct POC may be helpful, maintaining the position of the endoscope during the procedure is problematic. Fourth, cholangitis, pancreatitis can be additional procedure-related complications of direct POC. The most important procedure-related complication of direct POC is possible of air embolism [12].

This study had several limitations. First, the retrospective cohort may have introduced selection bias. Second, the number of patients was relatively small and there was no control group, limiting the statistical power. Third, the two endoscopists who performed direct POC were experienced in both that procedure and endoscopic retrograde cholangiography. Thus, prospective studies involving operators with a standard-

ized level of skill in direct POC are required to validate our findings.

Conclusions

In conclusion, selective biliary drainage under direct POC using an ultra-slim upper endoscope is feasible and safe for patients with a variety of clinical conditions. Although we have shown that drainage is feasible, it can only be used as a temporary measure to prevent the risk of cholangitis after direct POC. This is because only 5-Fr double-pigtail or straight plastic stent, and/or 5-Fr nasobiliary drainage catheters can be inserted through the POC system. Continuing development of the endoscopes and accessories is expected to facilitate the therapeutic application of direct POC.

Funding

This work was partly supported by SoonChunHyang University Research Fund.

Competing interests

The authors declare that they have no conflict of interest.

References

- [1] Moon JH, Terheggen G, Choi HJ et al. Peroral cholangioscopy: diagnostic and therapeutic applications. *Gastroenterology* 2013; 144: 276–282
- [2] Lee YN, Moon JH, Choi HJ et al. A newly modified access balloon catheter for direct peroral cholangioscopy by using an ultraslim upper endoscope (with videos). *Gastrointest Endosc* 2016; 83: 240–247
- [3] Moon JH, Ko BM, Choi HJ et al. Intraductal balloon-guided direct peroral cholangioscopy with an ultraslim upper endoscope (with videos). *Gastrointest Endosc* 2009; 70: 297–302
- [4] Chandrasekhara V, Khashab MA, Muthusamy VR et al. Adverse events associated with ERCP. *Gastrointest Endosc* 2017; 85: 32–47
- [5] Weinberg BM, Shindy W, Lo S. Endoscopic balloon sphincter dilation (sphincteroplasty) versus sphincterotomy for common bile duct stones. *Cochrane Database Syst Rev* 2006: Cd004890
- [6] Freeman ML, Nelson DB, Sherman S et al. Complications of endoscopic biliary sphincterotomy. *N Engl J Med* 1996; 335: 909–919
- [7] Waxman I, Chennat J, Konda V. Peroral direct cholangioscopy-guided selective intrahepatic duct stent placement with an ultraslim endoscope. *Gastrointest Endosc* 2010; 71: 875–878
- [8] Wright H, Sharma S, Gurakar A et al. Management of biliary stricture guided by the Spyglass Direct Visualization System in a liver transplant recipient: an innovative approach. *Gastrointest Endosc* 2008; 67: 1201–1203
- [9] Kumar S. Cholangioscopy-directed endoscopic intervention for post-liver transplantation anastomotic biliary stricture. *Gastrointest Endosc* 2015; 81: 1014–1015
- [10] Woo YS, Lee JK, Noh DH et al. SpyGlass cholangioscopy-assisted guidewire placement for post-LDLT biliary strictures: a case series. *Surgical Endoscopy* 2016; 30: 3897–3903
- [11] Shin JU, Lee JK, Kim KM et al. Endoscopic naso-gallbladder drainage by using cholangioscopy for acute cholecystitis combined with cholangitis or choledocholithiasis (with video). *Gastrointest Endosc* 2012; 76: 1052–1055
- [12] Efthymiou M, Raftopoulos S, Antonio Chirinos J et al. Air embolism complicated by left hemiparesis after direct cholangioscopy with an intraductal balloon anchoring system. *Gastrointest Endosc* 2012; 75: 221–223