

# A chronic sinus tract infection developing after suture anchoring of the ankle

## A case report

Woo Jong Kim, MD<sup>c</sup>, Ki Won Young, MD, PhD<sup>a</sup>, Chang Hyun Kim, MD<sup>c</sup>, Sung Hun Won, MD<sup>b</sup>, Kyu Hwan Bae, MD<sup>a</sup>, Hong Seop Lee, MD<sup>a,\*</sup>

### Abstract

**Rationale:** Suture anchors are increasingly used to fix soft tissue to bone. Favorable outcomes of the modified Brostrom operation (MBO) using suture anchors have been reported. However, to the best of our knowledge, few complications of suture anchors used in ankle surgery have been described. Here, we present a rare case of successful treatment of a chronic sinus tract infection developing after the MBO using a suture anchor.

**Patient concerns:** A healthy 18-year-old high school student presented with a chronic ulcerative wound in his right ankle 1 year after anterior talofibular and calcaneofibular ligament repair using a suture anchor at a local clinic. Clinical examination revealed a 1.5 × 2-cm-sized ulcerative wound, accompanied by a red-black discharge, on the anterior border of the right lateral malleolus. The wound could be approximated to the joint capsule level using a forceps.

**Diagnosis:** A simple standing anteroposterior radiograph of the right ankle revealed mild, lateral soft-tissue swelling. Magnetic resonance imaging showed that a sinus tract running from the wound to the talar body crossed the anterior joint capsule, and bone marrow edema surrounding the talus.

**Interventions:** We removed the sinus tract and the infected suture anchor. We rendered the wound zigzag-shaped and then performed simple suturing and applied a short leg cast.

**Outcomes:** The wound healed completely by 4 weeks after surgery. The patient reported no complication or recurrence of infection at the 1-year follow-up.

**Lessons:** To obtain wound healing, the chronic sinus tract must be removed. If the suture anchor is the cause of infection, it should be removed.

**Abbreviations:** AOFAS = American Orthopedic Foot and Ankle Society, ATFL = anterior talofibular ligament, CFL = calcaneofibular ligament, CLAI = chronic lateral ankle instability, MBO = modified Brostrom operation.

**Keywords:** modified Brostrom operation, sinus tract, suture anchor

## 1. Introduction

Suture anchors are increasingly used to fix soft tissue to bone.<sup>[1]</sup> The modified Brostrom operation (MBO) is the most widely used procedure for the correction of ankle instability.<sup>[2]</sup> Favorable

outcomes of the MBO using suture anchors have been reported.<sup>[1,3]</sup> The infection rate after such surgery is low: 0% to 4.5%.<sup>[1,2,4]</sup> However, a suture anchor is not free of complications because a suture anchor acts as an implant. After shoulder surgery, suture anchor complications include pull-out,<sup>[5,6]</sup> arthritis,<sup>[5]</sup> and osteolysis.<sup>[7]</sup> However, complications of suture anchors used in ankle surgery are rare. We encountered a chronic infection of the sinus tract after the MBO using a suture anchor. The wound healed completely after removal of the sinus tract and infected suture anchor.

## 2. Case description

This case report was approved by the Institutional Review Board of Eulji Medical Center, and the patient gave written informed consent. The patient was a healthy 18-year-old male who underwent anterior talofibular ligament (ATFL) and calcaneofibular ligament (CFL) repair using a suture anchor at a local clinic 1 month after being injured while playing soccer. There were no other injuries. The ATFL and CFL were repaired using a JuggerKnot 1.45-mm LongSoft Anchor (Zimmer Biomet, Warsaw, IN). The ATFL was repaired at the talar side and the CFL at the fibular side. According to the medical record of the first hospital, an infection featuring a purulent exudate developed in the surgical site 1 week after the operation. Irrigation and debridement were performed in the operating room every day for 10 days. The wound discharge and swelling decreased, and a

Editor: N/A.

WJK and KWY contributed equally to this study and should be considered co-first authors.

No benefit in any form has been or will be received from a commercial party related directly or indirectly to the subject of this article. The authors have no potential conflicts of interest to disclose.

<sup>a</sup> Department of Foot and Ankle Surgery, Eulji Medical Center, Eulji University, Nowongu, <sup>b</sup> Department of Orthopaedic Surgery, Soonchunhyang University Hospital Seoul, Yongsan-gu, Seoul, <sup>c</sup> Department of Orthopaedic Surgery, Soonchunhyang University Hospital Cheonan, Dongam-gu, Cheonan, Korea.

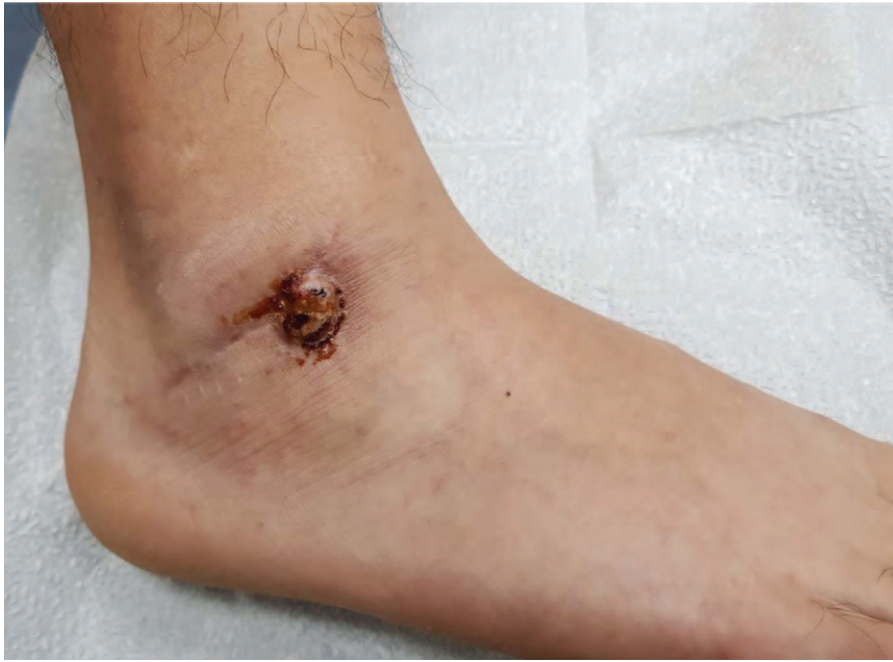\* Correspondence: Hong Seop Lee, Department of Foot and Ankle Surgery, Eulji Medical Center, Eulji University, 68, Hangeulbiseok-ro, Nowongu, Seoul, Korea, 01830 (e-mail: sup4036@naver.com).

Copyright © 2018 the Author(s). Published by Wolters Kluwer Health, Inc. This is an open access article distributed under the terms of the Creative Commons Attribution-Non Commercial License 4.0 (CCBY-NC), where it is permissible to download, share, remix, transform, and buildup the work provided it is properly cited. The work cannot be used commercially without permission from the journal.

Medicine (2018) 97:50(e13738)

Received: 11 September 2018 / Accepted: 27 November 2018

<http://dx.doi.org/10.1097/MD.0000000000013738>

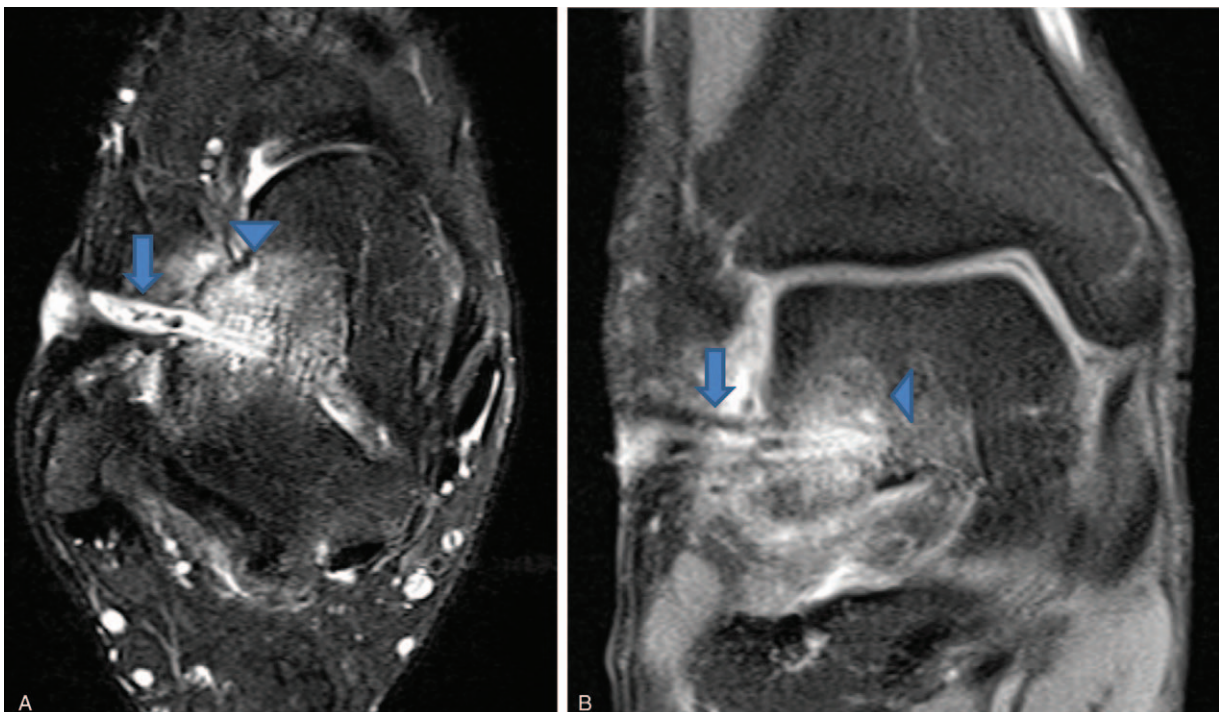


**Figure 1.** A 1.5 × 2-cm-sized ulcerative wound accompanied by a red-black discharge on the anterior border of the right lateral malleolus.

simple suture was placed. There was no evidence of wound infection, and the suture was removed and the patient discharged. However, abrupt wound discharge and dehiscence developed after suture removal. He did not visit that hospital again, for personal reasons, and personally dressed the chronic wound at home. He visited our outpatient clinic 1 year later.

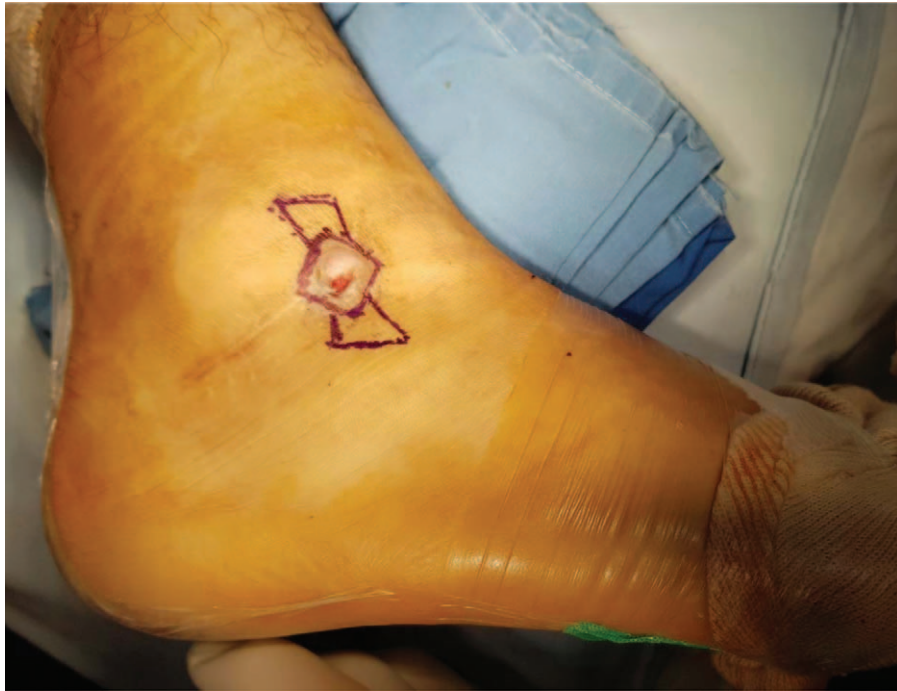A clinical examination revealed a 1.5 × 2-cm-sized ulcerative wound accompanied by a red-black discharge on the anterior

border of the right lateral malleolus (Fig. 1). We could approximate the wound to the joint capsule level by applying forceps at the wound site. A simple standing anteroposterior radiograph of the right ankle revealed mild lateral soft-tissue swelling. Magnetic resonance imaging revealed a sinus tract running from the wound to the talar body across the anterior joint capsule, and bone marrow edema surrounding the talus (Fig. 2). The American Orthopedic Foot and Ankle Society



**Figure 2.** A T2-weighted axial image (A) and a proton density coronal image (B) showing the sinus tract (arrow) running from the wound to the talar body (crossing the anterior joint capsule), and bone marrow edema (arrowhead) surrounding the talus.



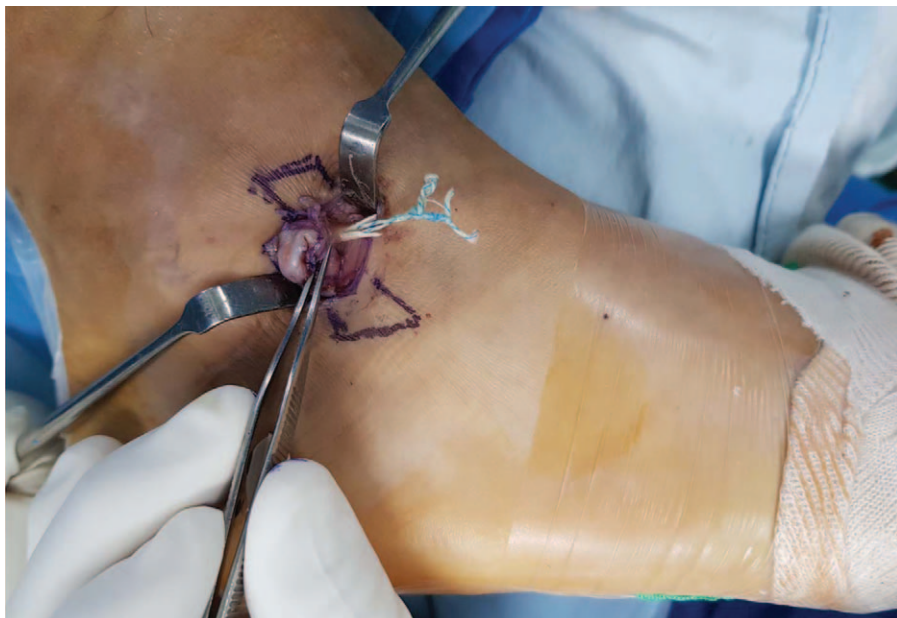


**Figure 3.** A rectangular skin incisions encompassing the ulcerative wound was created, followed by dissection along the chronically infected sinus tract.

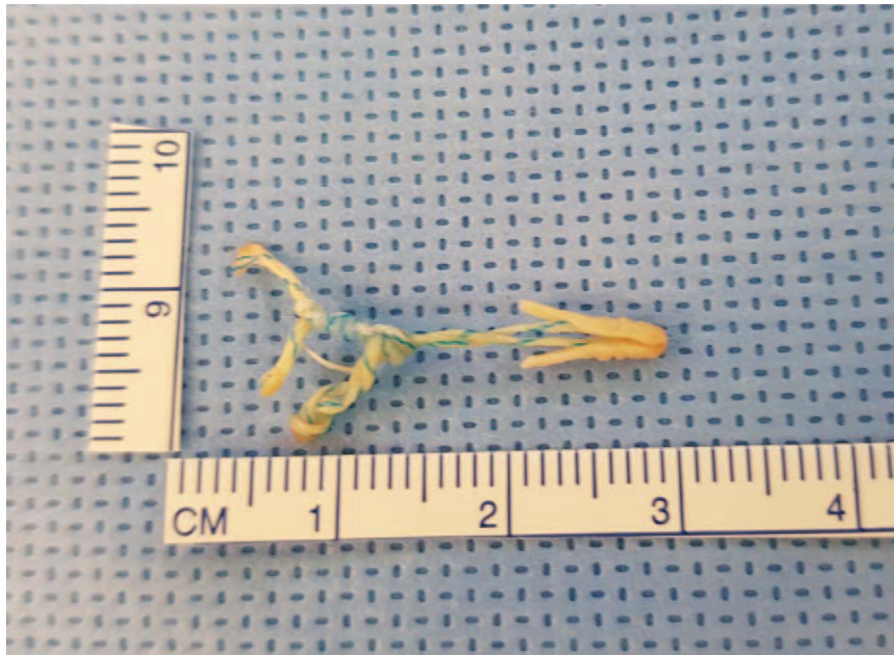(AOFAS) Ankle-Hind Foot score was 45. Intravenous vancomycin was commenced on the day of surgery.

In the operation theater, we excised the sinus tract, sent material for culture, and performed irrigation and debridement; our surgical approach was via the chronic ulcerative wound. Surgery was performed with the patient right side up in the lateral position after placement of a pneumatic tourniquet under general anesthesia. A rectangular skin incision encompassing the ulcerative wound was created, followed by dissection along

the chronically infected sinus tract (Fig. 3). Intraoperatively, the sinus tract was seen to lie on top of the suture anchor (Fig. 4). The suture anchor was loose and infected and was removed (Fig. 5). The chronically infected sinus tract was excised (Fig. 6) and a pathological examination was performed (Fig. 7). A hole through the sinus tarsi was evident near the wound; we performed wound culture (Fig. 8). As the surgical site was clean and no discharge was evident, we decided to perform immediate repair. As a rectangular wound cannot be easily sutured, we created



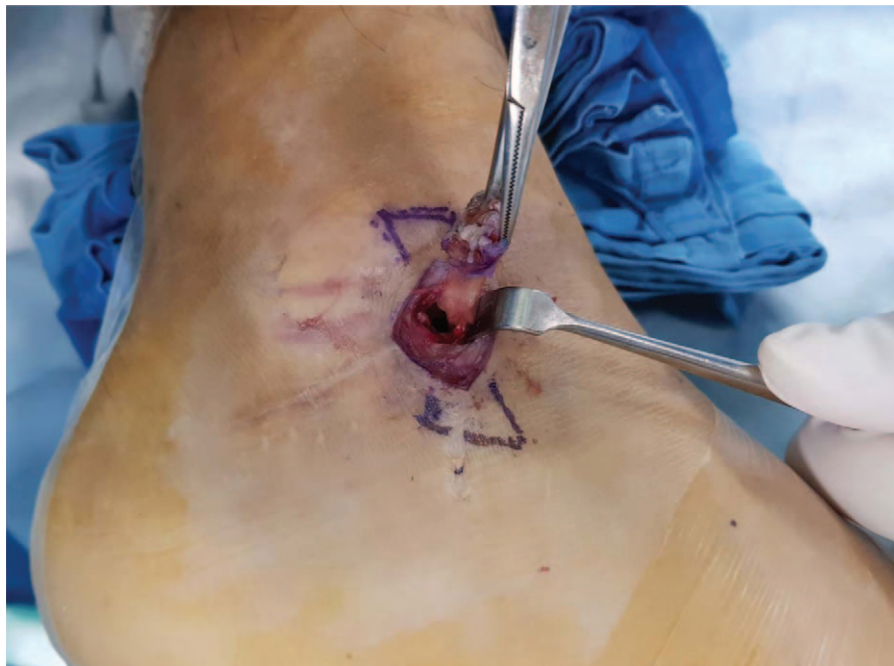**Figure 4.** Intraoperatively, the sinus tract was found to lie over the suture anchor. The anchor was loose and infected, and was removed.



**Figure 5.** The removed suture anchor.

rectangular superior and inferior skin flaps (Fig. 9). The anterior flap was lowered and the posterior flap raised to create a zigzag-shaped wound (Fig. 10). After simple suturing, a short leg cast was applied and the wound dressed through the cast window (Fig. 11). The patient received intravenous vancomycin during 14 days of hospitalization. He was discharged on postoperative day 14 with a 1-week prescription of oral amoxicillin/clavulanic acid. At 4 weeks postoperatively, we removed the suture and cast; no

wound dehiscence was evident. No bacterium grew on wound culture; the pathological diagnosis was chronic inflammation and abscess formation. He visited our outpatient clinic for scheduled follow-up at 12 months after surgery. The wound had completely healed (Fig. 12). He reported no symptoms of infection and regained full function of the right ankle. The anterior drawer test was negative. The AOFAS Ankle-Hind Foot score improved to 90.



**Figure 6.** The chronically infected sinus tract was excised.



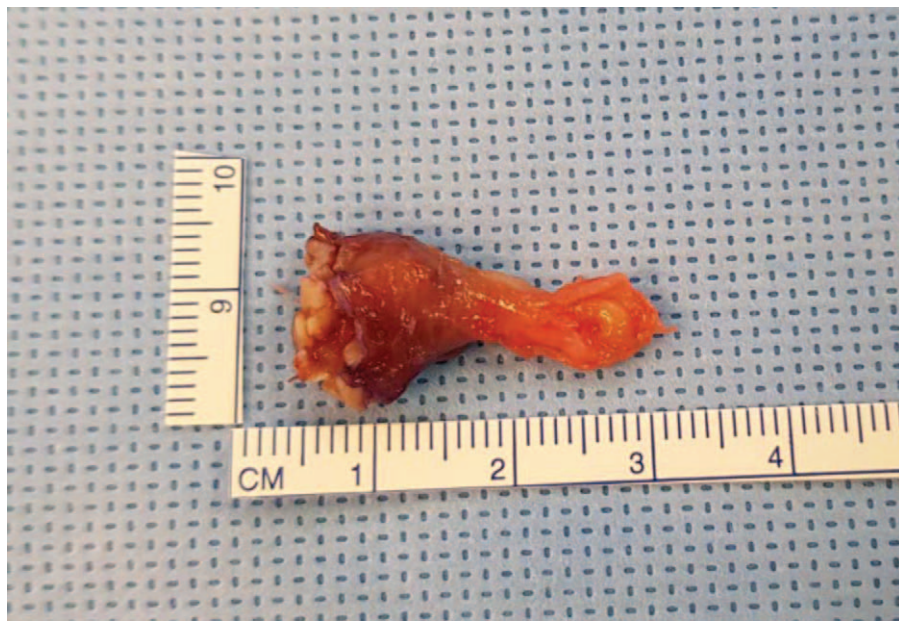

Figure 7. The sinus tract; pathological examination.

### 3. Discussion

Chronic lateral ankle instability (CLAI) is defined as an instability more than 6 months in duration, manifesting as repeated episodes of “giving out”, persistent pain, and an inability to resume the pre-injury activity level.<sup>[1]</sup> About 50 surgical procedures are available to treat CLAI. Anatomical repair of the ATFL and CFL can restore normal ankle and subtalar joint mechanics. The MBO is the most popular technique for anatomical reconstruction of

lateral ankle ligaments; the success rate is 85% to 90%.<sup>[8-10]</sup> Suture anchors were developed to facilitate soft tissue fixation to bone, and have been placed during both open and arthroscopic MBOs.<sup>[1-3,11,12]</sup> Such placement is technically simple and allows accurate ligament re-attachment to the normal anatomical origins.<sup>[1]</sup> However, suture anchors, being implants, can cause problems.<sup>[5,13,14]</sup> Reported complications associated with suture anchor used in shoulder surgery include pull-out,<sup>[5,15]</sup> arthritis,<sup>[5-7]</sup> and osteolysis.<sup>[7,16]</sup> To the best of our knowledge,

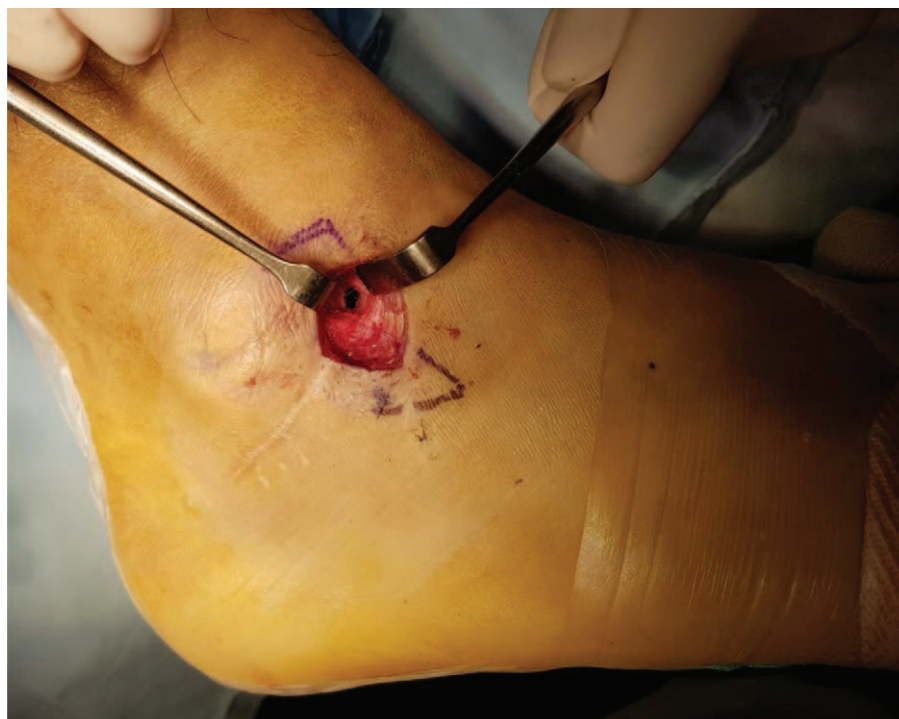
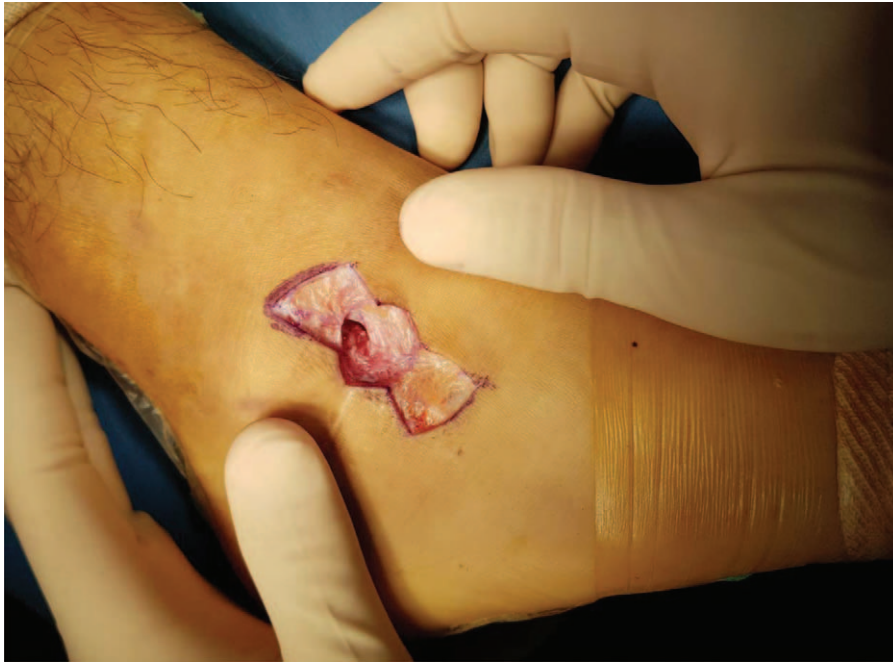
Figure 8. A hole through the sinus tarsi was evident at the wound site.



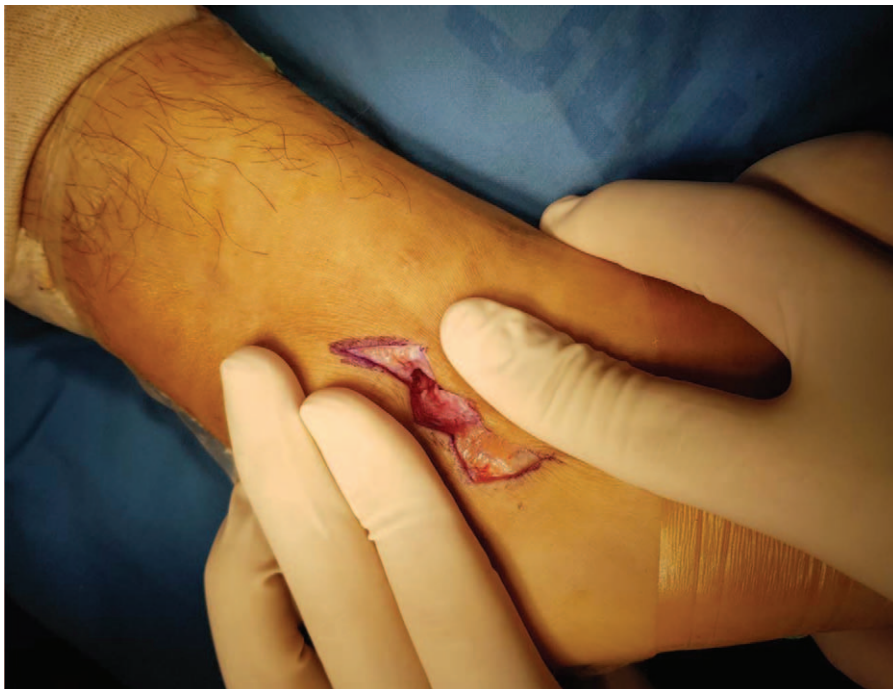**Figure 9.** Rectangular skin flaps were created superior and inferior to the wound.

complications associated with suture anchor use during ankle surgery have been rarely reported.

Suture anchors implanted during orthopedic surgery can cause infections, both perioperatively and postoperatively. In our present case, the exact cause of infection was unknown, but given that a chronically infected sinus tract lay over the suture anchor, the anchor is likely to have caused the infection. The removal of orthopedic implants is important to control infection. We

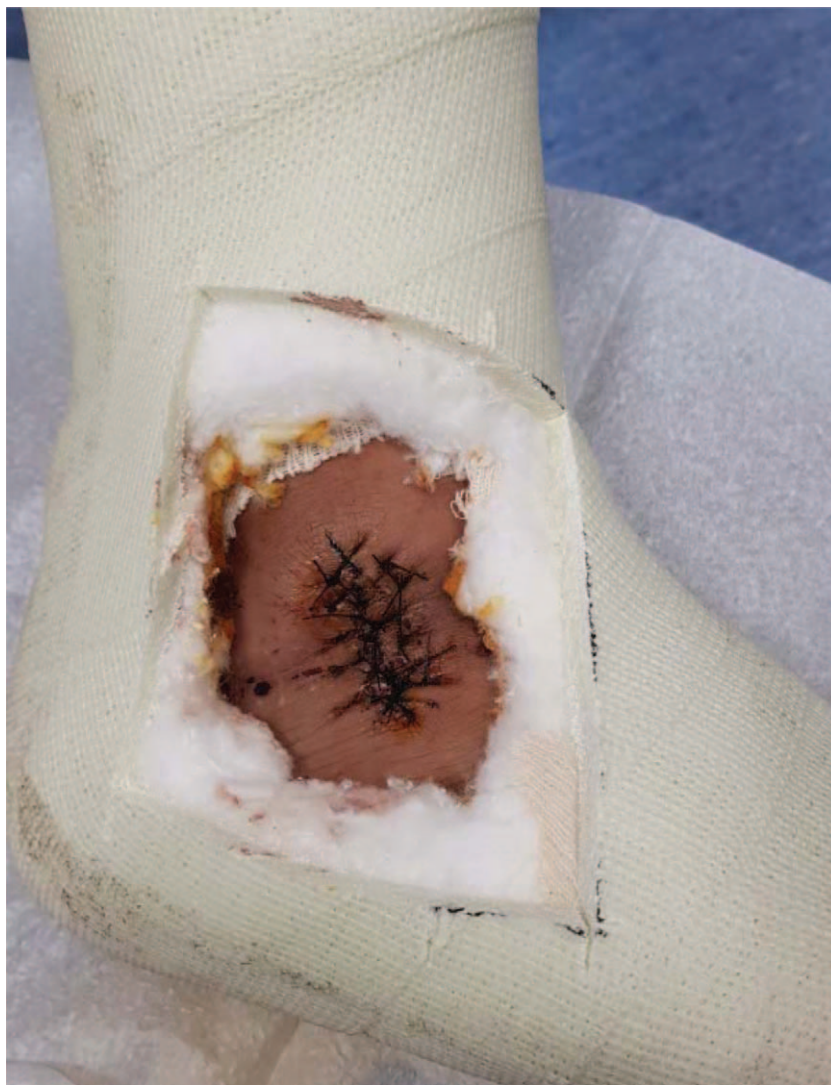removed the infected suture anchor and the chronically infected sinus tract; the wound healed after repair without infection recurrence.

A few reports have described the incidence and management of culture-negative infections developing after orthopedic surgery. Such infections arise after prior antibiotic treatment to counter infections with unusual organisms such as fungi, mycobacteria, or bacteria that form biofilms. Two case reports have

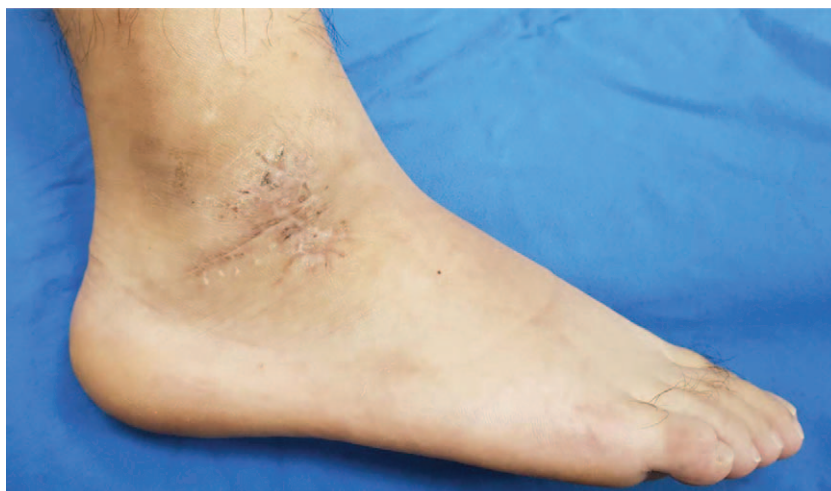

**Figure 10.** The anterior flap was lowered and the posterior flap raised to create a zigzag-shaped wound.





**Figure 11.** After simple suturing, a short leg cast was applied and the wound dressed through the cast window.



**Figure 12.** The wound exhibited no complication or recurrence of infection at the 1-year follow-up exam.

appeared.<sup>[17,18]</sup> Bacterial cultures were negative, but *Mycobacterium* was found in the wounds. This pathogen must be considered if, postoperatively, wounds present with chronically discharging sinuses, even in healthy non-immunocompromised patients. In our case, the sinus tract was chronically infected, but Gram staining and bacterial cultures were negative. We did not stain for acid-fast bacilli or seek to culture *Mycobacterium*; these tests should be considered in cases featuring the chronic infection of a sinus tract.

In conclusion, the MBO with placement of a suture anchor affords good results, but the anchor may become a source of infection. Removal of the chronically infected sinus tract and the infected suture anchor are required to heal the wound.

## Acknowledgments

The authors would like to thank the Soonchunhyang University Research Fund for support.

## Author contributions

**Conceptualization:** Woo Jong Kim.

**Investigation:** Ki Won Young.

**Software:** Sung Hun Won, Kyu Hwan Bae.

**Supervision:** Hong Seop Lee.

**Writing – original draft:** Hong Seop Lee.

**Writing – review & editing:** Chang Hyun Kim, Hong Seop Lee. Hong Seop Lee orcid: 0000-0002-3589-314X.

## References

- [1] Messer TM, Cummins CA, Ahn J, et al. Outcome of the modified Broström procedure for chronic lateral ankle instability using suture anchors. *Foot Ankle Int* 2000;21:996–1003.
- [2] Cho B-K, Kim Y-M, Kim D-S, et al. Comparison between suture anchor and transosseous suture for the modified-Broström procedure. *Foot Ankle Int* 2012;33:462–8.
- [3] Kim ES, Lee KT, Park JS, et al. Arthroscopic anterior talofibular ligament repair for chronic ankle instability with a suture anchor technique. *Orthopedics* 2011;34:273–1273.
- [4] Cho B-K, Kim Y-M, Park K-J, et al. A prospective outcome and cost-effectiveness comparison between two ligament reattachment techniques using suture anchors for chronic ankle instability. *Foot Ankle Int* 2015;36:172–9.
- [5] Kaar TK, Schenck RCJr, Wirth MA, et al. Complications of metallic suture anchors in shoulder surgery: a report of 8 cases. *Arthroscopy* 2001;17:31–7.
- [6] Park J-Y, Lhee S-H, Park H-K, et al. Perianchor radiolucency after knotless anchor repair for shoulder instability: correlation with clinical results of 69 cases. *Am J Sports Med* 2009;37:360–70.
- [7] Rhee YG, Lee D-H, Chun IH, et al. Glenohumeral arthropathy after arthroscopic anterior shoulder stabilization. *Arthroscopy* 2004;20:402–6.
- [8] Hamilton WG, Thompson FM, Snow SW. The modified Brostrom procedure for lateral ankle instability. *Foot Ankle* 1993;14:1–7.
- [9] Karlsson J, Eriksson BI, Bergsten T, et al. Comparison of two anatomic reconstructions for chronic lateral instability of the ankle joint. *Am J Sports Med* 1997;25:48–53.
- [10] Keller M, Grossman J, Caron M, et al. Lateral ankle instability and the Brostrom-Gould procedure. *J Foot Ankle Surg* 1996;35:513–20.
- [11] Li X, Killie H, Guerrero P, et al. Anatomical reconstruction for chronic lateral ankle instability in the high-demand athlete: functional outcomes after the modified Broström repair using suture anchors. *Am J Sports Med* 2009;37:488–94.
- [12] Shahrulazua A, Ariff Sukimin M, Tengku Muzaffar T, et al. Early functional outcome of a modified Brostrom-Gould surgery using bioabsorbable suture anchor for chronic lateral ankle instability. *Singapore Med J* 2010;51:235.
- [13] Ticker JB, Lippe RJ, Barkin DE, et al. Infected suture anchors in the shoulder. *Arthroscopy* 1996;12:613–5.
- [14] Benson EC, MacDermid JC, Drosdowech DS, et al. The incidence of early metallic suture anchor pullout after arthroscopic rotator cuff repair. *Arthroscopy* 2010;26:310–5.
- [15] Tingart MJ, Apreleva M, Lehtinen J, et al. Anchor design and bone mineral density affect the pull-out strength of suture anchors in rotator cuff repair: which anchors are best to use in patients with low bone quality? *Am J Sports Med* 2004;32:1466–73.
- [16] Athwal GS, Shridharani SM, O'driscoll SW. Osteolysis and arthropathy of the shoulder after use of bioabsorbable knotless suture anchors: a report of four cases. *JBJS* 2006;88:1840–5.
- [17] Kim J-H, Kim J-Y, Sagong S-Y. *Mycobacterium tuberculosis* infection in the shoulder after reverse total shoulder arthroplasty. *J Korean Orthop Assoc* 2015;50:154–9.
- [18] Ng SW, Han Y, Lee D. Lessons learnt from an atypical *Mycobacterium* infection post-anterior cruciate ligament reconstruction. *Clin Orthop Surg* 2015;7:135–9.