

# Clinical significance of early venous enhancement on CT angiography of the ischemic lower limbs

Je Yeon Byeon, MD<sup>a</sup>, Si Hyun Kwak, MD<sup>a</sup>, Hwan Jun Choi, MD, PhD<sup>a,b,\*</sup> , Jun Hyuk Kim, MD, PhD<sup>a</sup>, Da Woon Lee, MD<sup>a</sup>

## Abstract

The authors observed good clinical courses in patients with lower limb ulcers and extensive skin inflammation who showed early venous enhancement at contrast-enhanced lower extremity computed tomographic angiography. The author hypothesized that these early venous enhancements tend to occur in conditions of healthier vascular status. A total of 145 patients who met the inclusion criteria were classified based on the degree of arterial occlusion and early venous enhancement according to lower extremity angiography. Early venous enhancement correlated with age over 65 (t-score = 0.001), absence of ulcer history (t-score = 0.003), absence of amputation history (t-score = 0.004), and low ankle-brachial index ( $P$  value = .001). We confirmed that the factors related with early venous enhancement differ from the factor inducing arterial occlusion. Prior to this study, early enhancement of veins in the lower limb was thought to be an artifact. However, in this study, veins that show early enhancement are suspected of being healthier and more responsive to inflammation than those that do not show early enhancement. These findings may help to predict the clinical course and to determine therapeutic planning without additional studies. Also, it can be easily reproduced in other facilities.

**Abbreviations:** ABI = ankle-brachial index, CTA = computed tomographic angiography, PAD = peripheral arterial disease, VE = venous enhancement.

**Keywords:** angiography, artifacts, lower extremities, veins

## 1. Introduction

Lower limb peripheral arterial disease (PAD) is the most common vascular disease related to chronic obstructive disease caused by atherosclerosis of the descending aorta below the renal artery and arteries of the lower limb.<sup>[1]</sup> Prolonged ischemia induces intermittent claudication, pain at rest, and arterial ulcers.<sup>[2]</sup> Although PAD is the most common cause of lower extremity ischemia, the condition can be caused by a variety of other factors.<sup>[2,3]</sup> Most patients visiting the hospital for acute limb ischemia have a history of acute limb ischemia, including aortic or peripheral arterial embolism or thrombotic sequelae, traumatic vesicular disease, and Buerger disease.<sup>[3,4]</sup>

About 40% of PAD patients are asymptomatic, 50% have atypical symptoms, and only about 10% show typical symptoms such as claudication.<sup>[5]</sup> Without early diagnosis and appropriate care, patients may need to undergo limb amputation.<sup>[2-4]</sup> Therefore, several vascular and wound assessment methods have been developed to aid the appropriate diagnosis of PAD, including contrast-enhanced lower extremity computed tomographic angiography (CTA),<sup>[6]</sup> ankle-brachial index (ABI),<sup>[7]</sup> the angiosome concept,<sup>[8]</sup> basic blood profile

work-up,<sup>[9,10]</sup> coagulopathy, and elevated inflammation markers.<sup>[9,10]</sup> The degree and prognosis of diabetic ulcers can be assessed using Rutherford, Wagner, and University of Texas classifications.<sup>[11,12]</sup> Among them, CTA is highly sensitive and accurate diagnostic instruments that help to quickly identify the occlusion site and visualize the anatomical location.<sup>[13]</sup> CT angiography was found to be a reliable mean for pathoanatomical description of the arterial lesions in critical lower limb ischemia.<sup>[14]</sup>

In general, contrast-enhanced CTA was performed to identify the arterial phase in situations where ischemia was suspected,<sup>[15]</sup> sometimes the veins were enhanced in the artery phase. These enhanced veins have been considered artifacts or have no special meaning.<sup>[16,17]</sup> However, studies by Sasaki et al<sup>[18]</sup> and Parthasarathy et al<sup>[19]</sup> found that under an ischemic condition, VE could provide information about collateral perfusion and information about the prognosis for ischemia. However, there has been no study of the clinical implications of VE in the lower limbs. The authors observed good clinical courses in patients with lower limb ulcers and extensive skin inflammation who showed early VE (Figs. 1 and 2). So, we hypothesized that early VE in ischemic limb was thought to

This work was supported by the National Research Foundation of Korea (NRF) grant funded by the Korea Government (MSIT) (2020R1A2C1100891), and was supported by Soonchunhyang University research fund.

The authors have no conflicts of interest to disclose.

The datasets generated during and/or analyzed during the current study are available from the corresponding author on reasonable request.

<sup>a</sup> Department of Plastic and Reconstructive Surgery, Soonchunhyang University Cheonan Hospital, Cheonan, Korea, <sup>b</sup> Institute of Tissue Regeneration, College of Medicine, Soonchunhyang University, Cheonan, Korea.

\* Correspondence: Hwan Jun Choi, Department of Plastic & Reconstructive Surgery, Soonchunhyang University Cheonan Hospital, Soonchunhyang University College of Medicine, Bongmyeong-dong, Dongnam-gu, Cheonan-si, Chungcheongnam-do 330-721, Korea (e-mail: medi619@hanmail.net).

Copyright © 2022 the Author(s). Published by Wolters Kluwer Health, Inc. This is an open-access article distributed under the terms of the Creative Commons Attribution-Non Commercial License 4.0 (CCBY-NC), where it is permissible to download, share, remix, transform, and buildup the work provided it is properly cited. The work cannot be used commercially without permission from the journal.

How to cite this article: Byeon JY, Kwak SH, Choi HJ, Kim JH, Lee DW. Clinical significance of early venous enhancement on CT angiography of the ischemic lower limbs. *Medicine* 2022;101:39(e30560).

Received: 6 May 2022 / Received in final form: 9 August 2022 / Accepted: 11 August 2022

<http://dx.doi.org/10.1097/MD.00000000000030560>

be a phenomenon in which the venous return was increased by inflammatory responses, so it was assumed that an appropriate inflammatory response could be associated with a good clinical course. Therefore, author evaluate how early venous enhancement can be evaluated and quantified so that the results can be interpreted objectively. Also, author assessed the clinical

implications of early VE by investigating its associations with other factors, clinical course, amputation, and other assessment outcomes.

## 2. Methods

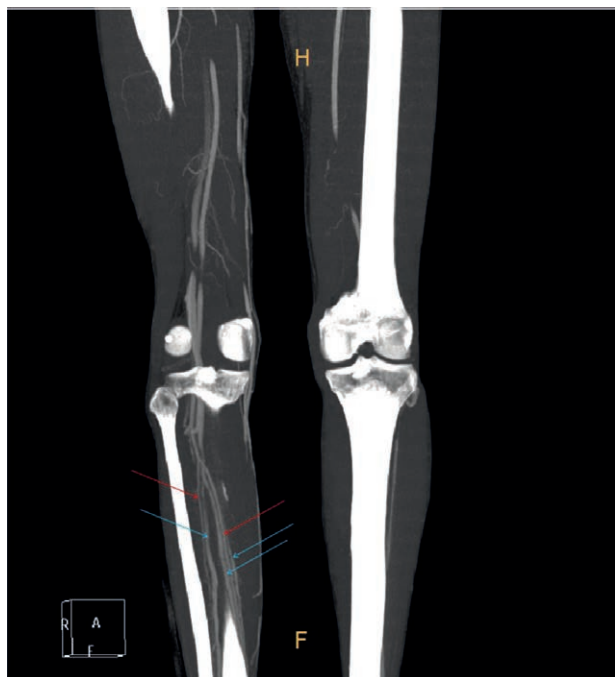
### 2.1. Study design and population

Medical records of patients who underwent contrast-enhanced lower extremity CTA between May 2013 and October 2017 at the Department of Plastic and Reconstructive Surgery at Soonchunhyang University Cheonan Hospital were reviewed retrospectively. The study protocol conformed to the ethical guidelines of the Declaration of Helsinki, as reflected in the approval by the Soonchunhyang University Hospital (Cheonan, South Korea) human research review committee. Institutional Review Board (IRB) of Soonchunhyang University Cheonan Hospital (IRB FILE No.: 2022-01-020) reviewed. All participants provided written informed consent for the publication before study.

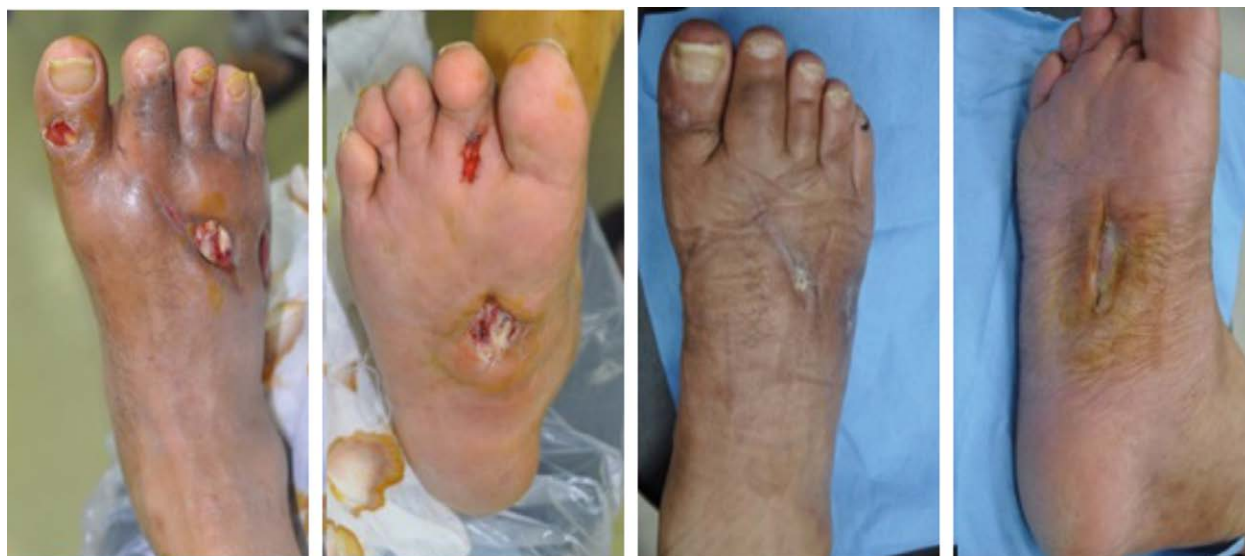A total of 602 patients who underwent contrast-enhanced lower extremity CTA during the study period were enrolled. The exclusion criteria were as follows: no images at the time of hospital admission or during contrast-enhanced lower extremity CTA to assess the wounds; loss to follow up, missing information on medical documents; no blood test at the time of admission or after contrast-enhanced lower extremity CTA; contralateral blood vessels were not healthy, precluding comparison with the affected side, that is, patients with vascular compromise on both legs; and nonvascular ulcers that were induced by motor disability or neuropathy. A total of 457 patients were excluded, resulting in 145 patients being included in the final analysis. Selective bias may occur while targeting patients who have had CT.

### 2.2. Data collection

The following data were collected: age, sex, ABI, date of symptom onset, cause of ulcers, location of ulcers, history of ulcers, smoking history, history of hypertension, history of chronic renal failure, history of diabetes mellitus, history of amputation, height, weight, body mass index (BMI), glycosylated



**Figure 1.** Arterial and venous enhancement seen at CTA. The red arrow shows the arteries that run to the periphery without narrowing or obstruction. The blue arrows indicate veins that accompany these arteries. If the enhancement is simply an error caused by differing rate of contrast medium injection and CT scan timing, the superficial and deep veins on the contralateral side would show enhancement; however, in this case, deep veins on the affected side showed earlier enhancement than did those on the healthy side. CTA = computed tomographic angiography.



**Figure 2.** The clinical course of an example case. A 54-year-old man with uncontrolled diabetes, hypertension, and 45 pack-year smoking history. Cellulitis and abscess that developed after stepping on a sharp metal plate progressed to an ulcer, causing soft tissue loss with ligament exposure on the dorsum of the foot. The patient had been treated by orthopedics but was transferred to plastic surgery, as no improvements were seen. The patient underwent debridement and irrigation for 2 weeks until new healthy granulation tissues formed, and successfully reached secondary recovery after 2 months without additional surgical treatment.

hemoglobin (HbA1c), hemoglobin/hematocrit (Hb/Hct), white blood cell (WBC) count, platelet (Plt) count, blood urea nitrogen/serum creatinine (BUN/Cr), erythrocyte sedimentation rate (ESR), and C-reactive protein (CRP) level; the following vessels were evaluated by contrast-enhanced CTA: anterior tibial, posterior tibial, peroneal, dorsalis pedis, medial calcaneal, lateral calcaneal, medial plantar, and lateral plantar; all were evaluated for arterial and VE using Hounsfield (HU).

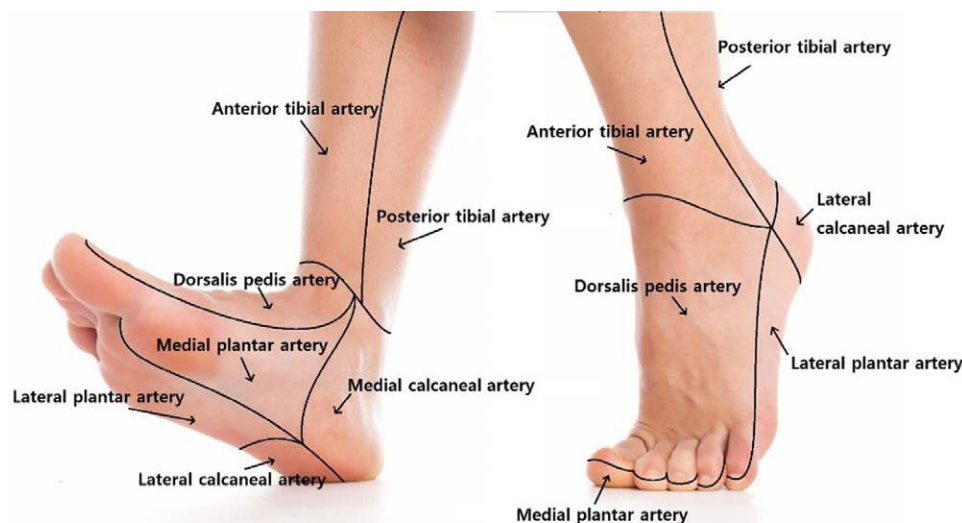
Ulcer location was classified as foot dorsum, medial plantar, lateral plantar, medial heel, lateral heel, and antetibial. When ulcers developed in several locations, all the locations were recorded, and when one ulcer infiltrated several areas, all the affected sites were recorded based on the angiosome concept (Fig. 3).<sup>[8]</sup> Patients with ulcer history were defined as those who completed ulcer treatment as an inpatient or outpatient, and patients with amputation history were defined as those who underwent amputation and completed treatment at the amputation site. Smoking history was divided into individuals who never smoked and smokers. Hypertension was defined as systolic blood pressure of >140 mm Hg or diastolic blood pressure of >90 mm Hg. Chronic renal failure was defined as an eGFR or below 30%. Diabetes mellitus was defined as a fasting blood glucose of >126 mg/dL, random blood glucose of >200 mg/dL, and HbA1c of >6.5. HbA1c, Hb/Hct, WBC, Plt, BUN/Cr, ESR, and CRP were measured as standard blood test results. Wound assessment was performed based on photographs of diabetic ulcer patients taken early in admission and during contrast-enhanced lower extremity CTA.

Contrast enhancement of the anterior tibial, posterior tibial, peroneal, dorsalis pedis, medial calcaneal, lateral calcaneal, medial plantar, and lateral plantar arteries and veins were compared between the affected side and healthy side, and the results were divided into noncontrast enhancement and contrast enhancement. The enhancement determined the degree of increase in brightness (HU) of vessels in CT angiograph. The noncontrast enhancement was defined as no increase in brightness (HU) of vessels. Author defined arterial occlusion as narrowing of blood flow through an artery. Early contrast enhancement of the veins was assessed for the degree of enhancement compared to the normal leg. The degree of

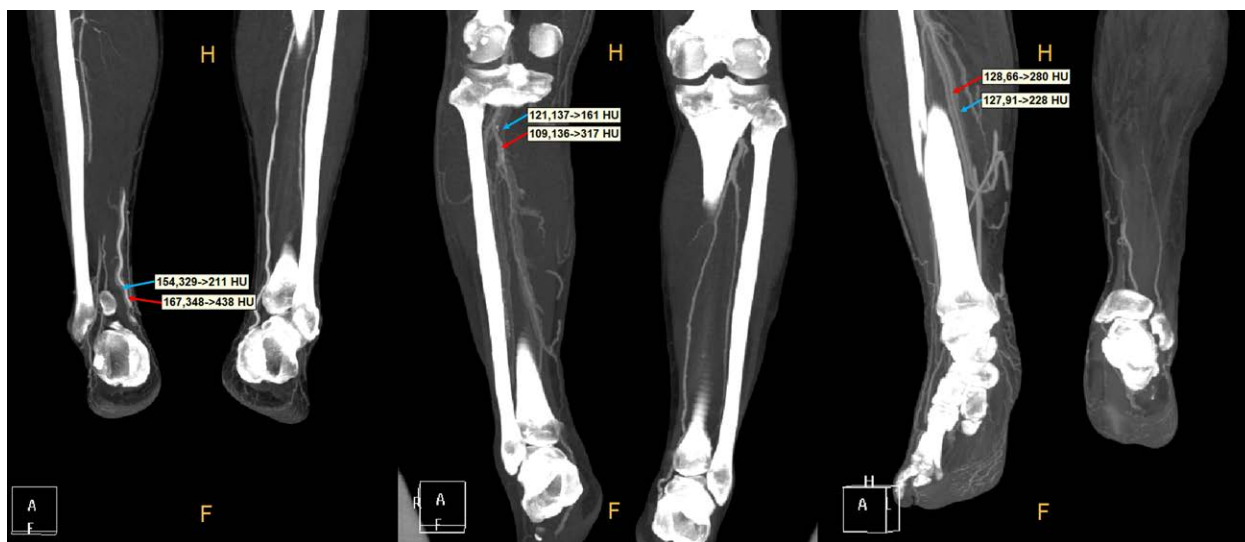
enhancement was analyzed through statistics and the presence or absence of early venous enhancement was defined. Data were collected on the degree of enhancement of arteries and veins that occurred at the anatomical location (Fig. 4). The degree of occlusion of the arteries was based on the reading of the specialists in the department of imaging, and the authors organized the data based on the above definition of whether the veins were early enhanced by measuring the HU value. The Philips Brilliance Ict 256 Slice (Philips North America Corporation, Andover, MA) was used with the following settings: standard Resolution, 32 × 0.625 collimation, 0.905 pitch, 1.0 s rotation time, 440 m FOV, standard filter and reconstruction). At the beginning of the imaging, 30 ml of normal saline was intravenously administered for 6 seconds at 5.0 mL/s, after which 135 mL of contrast medium (Bonorex Injection, DaiHanInc, Republic of Korea, Daejeon) and 15 mL of normal saline was mixed and administered at 5.0 mL/s for 30 seconds. Finally, 20 mL of contrast medium and 30 mL of normal saline was mixed and administered at 5.0 mL/s for 10 seconds (Fig. 5).

### 2.3. Statistical analysis

Among the clinical and laboratory parameters, categorical variables were expressed as means with standard deviation (SD) or medians. Categorical variables were expressed as frequencies with percentage (%) and compared with the chi-squared test or Fisher exact test, as appropriate. Correlation and linear regression were performed on ulcer locations in arteries where occlusion occurred and veins in which early enhancement occurred, respectively. Among the variables associated with the occlusion of blood vessels, those that could be substituted for categorical variables were substituted for categorical types to perform linear regression analysis and correlation analysis, and other continuous variables were performed separately for linear regression analysis and correlation. Two sample t-tests, Wilcoxon rank-sum test and contingency table analysis, were used to compare arterial occlusion and early venous enhancement. 10-fold cross-validation was used to improve reliability. Forward selection was



**Figure 3.** Ulcer location based on angiosome concept. Ulcer location was classified as foot dorsum, medial plantar, lateral plantar, medial heel, lateral heel, and antetibial. When ulcer developed in several locations, all locations were recorded, and when one ulcer infiltrated several areas, all affected sites were recorded. Ulcer location was Figure 1, and Figure 2 are the same patient. As you can see in Figure 1, the veins pointed by the blue arrow are early enhanced veins. If you compare it with the opposite leg, you will see for more certainty. The normal leg shows only arteries, while the lesional leg shows arteries and early enhanced veins at the same time. Figures 1 and 2 are the same patient. As you can see in Figure 1, the veins pointed by the blue arrow are early enhanced veins. If you compare it with the opposite leg, you will see for more certainty. The normal leg shows only arteries, while the lesional leg shows arteries and early enhanced veins at the same time. Analyzed in relation to the occlusion of arteries or early enhancement of veins in the corresponding angiosome units.



**Figure 4.** Evaluation of arterial and venous enhancement in CTA. This is a CTA of 3 different patients. In the normal leg, only the arteries are enhanced by the contrast and in the leg on the side of the disease, both the arteries and the veins can be seen to be enhanced by the contrast. The blue arrow means the brightness of the veins, and the red arrows mean the brightness of the arteries. CTA = computed tomographic angiography.

used as variable selection method. Statistical analyses were performed by SPSS software (Version 20.0; SPSS Inc., Chicago, IL). Statistical significance was set at a *P* value and t-score of below 0.05.

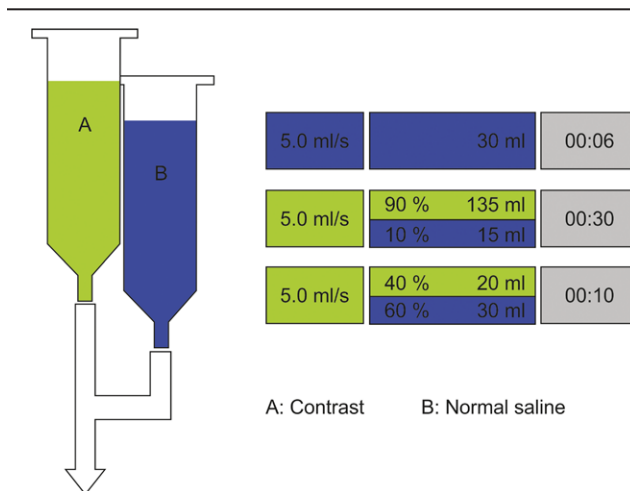
**3. Results**

The mean age of the 145 patients was 61.64 years. There was a greater proportion of men (*n* = 106) and women (*n* = 39). The mean right and left ABI were 1.049 and 1.047, respectively. One hundred and one patients did not have a history of ulcer treatment while 44 patients did. Seventeen patients had a history of amputation, while 128 patients did not. One hundred and six patients had a history of diabetes mellitus (Table 1).

Regarding ulcer location, the greatest number of ulcers was found in the foot dorsum (89, 43.80%), followed by medial plantar (47, 23.20%), lateral plantar (28, 13.80%), lateral heel (15, 7.40%), medial heel (14, 6.90%), and antetibial (8, 3.90%). There were no wounds in 2 cases (1.00%). The average brightness of the enhancement in the arteries was 490 HU, and the average brightness of the enhancement in the veins was 296 HU. For the contrast enhancement of the veins, the brightness of the enhancement was about half the brightness of the arterial enhancement, which was statistically significant. (*P* < .0001). (Fig. 6).

Complete arterial occlusion was found in 41 patients, and it most occurred in the dorsalis pedis artery (*n* = 41), followed by the anterior tibial artery (*n* = 28), the medial plantar artery (*n* = 21), the lateral plantar artery (*n* = 20), the lateral calcaneal artery (*n* = 15), and the medial calcaneal artery (*n* = 11). Ninety-two patients showed VE of the posterior tibial artery, and 91 patients showed VE of the medial plantar artery. Ninety patients showed VE of the lateral plantar and medial calcaneal arteries. Enhancement of the peroneal, lateral calcaneal, dorsalis pedis, and anterior tibial veins was shown in 81, 79, 72 and 64 patients, respectively. The relationship between each blood vessel and skin area was assessed based on the angiosome concept.<sup>18</sup> Complete arterial occlusion and ulcer location were significantly associated (*P* = .042); however, early VE and ulcer location were not significantly associated (*P* = .886) (Table 2).

Arterial occlusion was significantly associated with old age (>65 years) (t-score < 0.0001), hypertension (t-score = 0.004), low ABI (*P* < .0001), and diabetes (t-score = 0.07). However, it



**Figure 5.** Schematic diagram. Bonorex (Daihan Pharmaceutical, Daejeon, Republic of Korea) was used as the contrast medium, and normal saline was used. A volume of 30 mL of normal saline was intravenously administered for 6 s at 5.0 mL/s, after which 135 mL of contrast medium and 15 mL of normal saline was mixed and administered at 5.0 mL/s for 30 s. Finally, 20 mL of contrast medium and 30 mL of normal saline was mixed and administered at 5.0 mL/s for 10 s.

was not significantly associated with sex (t-score = 0.118), ulcer history (t-score = 0.568), amputation history (t-score = 0.754), smoking history (t-score = 0.147), chronic renal failure (t-score = 0.200), BMI (*P* = .60), HbA1c (*P* = .492), Hb/Hct (*P* = .443/0.651), WBC (*P* = .724), Plt (*P* = .401), BUN (*P* = .318), Serum Cr (*P* = .59), ESR (*P* = .152), or CRP (*P* = .855). By contrast, early VE was significantly associated with old age (>65 years) (t-score = 0.001), absence of ulcer history (t-score = 0.003), no history of amputation (t = 0.048), low ABI (*P* = .001), high Hb/Hct (*P* = .032/*P* = .008), and low CRP (*P* = .004). Furthermore, it was not significantly associated with sex (t-score = 0.782), smoking history (t-score = 0.13), hypertension (t-score = 0.253), chronic renal failure (t-score = 0.284), diabetes mellitus (t-score = 0.797), HbA1c (*P* = .412), WBC (*P* = .657), Plt (*P* = .819), BUN (*P* = .654), Serum Cr (*P* = .906), or ESR (*P* = .116) (Tables 3 and 4).

**Table 1**  
Demographic data of the study population.

Parameter	n = 145
Age, y	61.64
Sex	
Male	106
Female	39
ABI	
Right	1.049
Left	1.047
Ulcer history	
None	101
Present	44
Amputation history	
None	128
Present	17
Smoking history	
None	101
Present	44
Hypertension	
None	61
Present	84
Chronic renal failure	
None	121
Present	24
Diabetes mellitus	
None	39
Present	106

ABI = ankle-brachial index.

**4. Discussion**

We found that complete arterial occlusion was associated with ulcer location. This is in line with the angiosome concept that suggests that each area of the body receives its blood supply from corresponding blood vessels.<sup>[8]</sup> However, early VE was not significantly associated with ulcer location. This may result from ischemia promoting the development of collateral circulation, thereby inducing collateral circulation. Early enhancement can be observed in veins accompanying nonoccluded arteries

**Table 2**  
Correlation of ulcer location with the vascular status.

Ulcer location	Arterial occlusion		Early venous enhancement			
	Antetibial	8 (3.9%)	ATA	28	ATV	64
Foot dorsum	89 (43.8%)		DP	41	DPV	72
			PTA	15	PTV	92
Medial heel	14 (6.9%)		MC	11	MCV	90
Medial plantar	47(23.2%)		MP	21	MPV	91
Lateral plantar	28 (13.8%)		LP	20	LPV	90
Lateral heel	15 (7.4%)		PA	10	PV	81
None	2 (1.0%)		LC	15	LCV	79
			P value	.042*	P value	.886

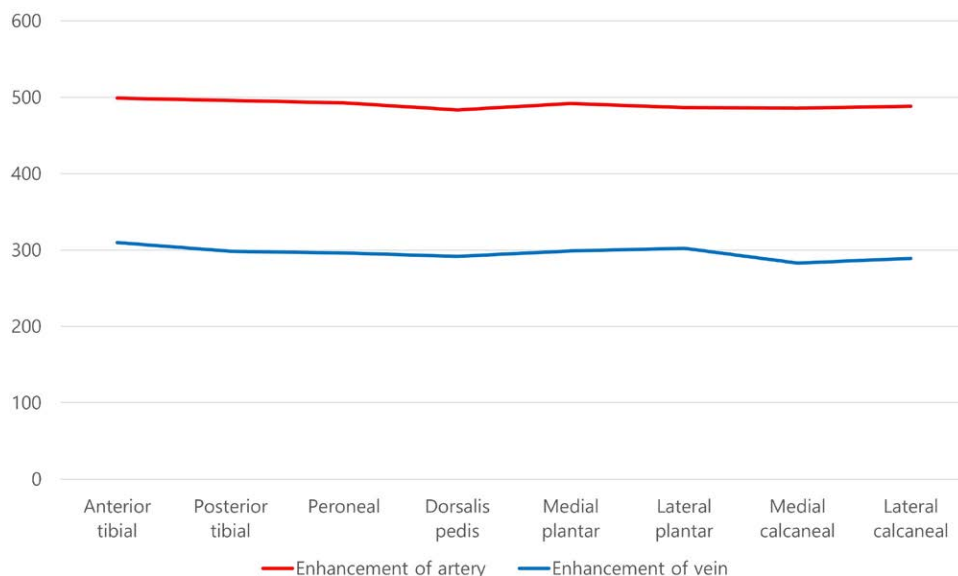
ATA = anterior tibial artery, ATV = anterior tibial vein, DP = dorsalis pedis artery, DPV = dorsalis pedis vein, LC = lateral calcaneal artery, LCV = lateral calcaneal vein, LP = lateral plantar artery, LPV = lateral plantar vein, MC = medial calcaneal artery, MCV = medial calcaneal vein, MP = medial plantar artery, MPV = medial plantar vein, PA = peroneal artery, PTA = posterior tibial artery, PTV = posterior tibial vein, PV = peroneal vein.

\* Wald confidence intervals were calculated. A regression with all covariates was conducted, and coefficients from it were summarized. P value was computed by correlation analysis.

because of an anastomosis among adjacent veins.<sup>[20,21]</sup> In our study, VE seemed to appear more in the presence of collateral vessels.

In an experiment inducing ischemia by forming a thrombus in the middle cerebral artery in African green monkeys, Sasaki et al<sup>[18]</sup> reported that the group showing early enhancement on contrast-enhanced CT showed less functional loss, such as palsy, compared to the group not showing early enhancement, and that most cases in the early enhancement group had well developed collateral circulation. It was hypothesized that venous outflow was present in the collateral-rich group and absent in the collateral poor group. Parthasarathy et al<sup>[19]</sup> suggested that this phenomenon is also evident in humans and observed that subjects with ischemic brain injuries show early VE in angiography and positive clinical course, though the specific pathophysiology underlying early VE was unknown.

Average Brightness of Enhancement



**Figure 6.** Enhancement of arteries and veins. Both arteries and veins had no difference in brightness depending on location ( $T < 0000.1$ ). The average brightness of the arteries was 490 HU, and the average brightness of the veins was 296 HU. The average brightness of the veins was about half that of the arteries, which was statistically significant ( $P < .1$ ).

Downloaded from http://journals.lww.com/md-journal by BMDM5ePHKav1zEoum1QIN4a+kLLHEZgbsIHo4XMIIOhCy WCX1AWWYQpIIOHID33D00dRy7TVSF4C3VC4OAVpDDa8KKGKv07my+78= on 04/30/2024

**Table 3**  
Differences and correlations among arterial occlusion, early venous enhancement, and independent variables.

	Arterial occlusion	Early venous enhancement
Sex		
Male	4.35	5.7
Female	3.48	6.1
t-score	0.118	0.782
Age, y		
<65	2.43	4.26
≥65	6.23	7.77
t-score	0.000*	0.001*
Ulcer history		
None	4	6.55
Present	4.36	4.09
t-score	0.568	0.003*
Amputation history		
None	3.96	6.05
Present	5.24	4
t-score	0.754	0.048*
Smoking history		
None	4.41	5.16
Present	3.98	6.09
t-score	0.147	0.13
Hypertension		
None	2.72	5.07
Present	4.97	6.32
t-score	0.004*	0.253
Chronic renal failure		
None	3.93	5.96
Present	5.04	5.04
t-score	0.2	0.284
Diabetes mellitus		
None	3.08	5.74
Present	5.84	8.78
t-score	0.07*	0.797
Amputation undergo		
No	3.82	5.82
Yes	5.32	5.75
t-score	0.432	0.632

\* *P* value was computed by 2-sample *t*-test and contingency table analysis.

**Table 4**  
Differences and correlations among arterial occlusion, early venous enhancement, and independent variables.

	Arterial occlusion	<i>P</i> value	Early venous enhancement	<i>P</i> value
Low ABI	0.752	.000*	0.639	.001*
BMI	0.044	.6	-0.158	.058
HbA1c	-0.063	.492	-0.075	.412
Hb/Hct	1.684	.443/.651	0.178	.032/.008*
WBC	0.03	.724	-0.037	.657
Platelet	-0.07	.401	-0.019	.819
BUN	0.083	.318	0.038	.654
Serum Cr	0.045	.59	-0.01	.906
ESR	0.012	.152	-0.131	.116
CRP	0.015	.855	-0.241	.004*

ABI = ankle-brachial index, BMI = body mass index, BUN = blood urea nitrogen, CRP = C-reactive protein, ESR = erythrocyte sedimentation rate, HbA1c = glycated hemoglobin, Hb/Hct = hemoglobin/hematocrit, Serum Cr = serum creatinine, WBC = white blood cell.

\* Wald confidence intervals were calculated. A regression with all covariates was conducted, and coefficients from it were summarized. *P* value was computed by correlation analysis.

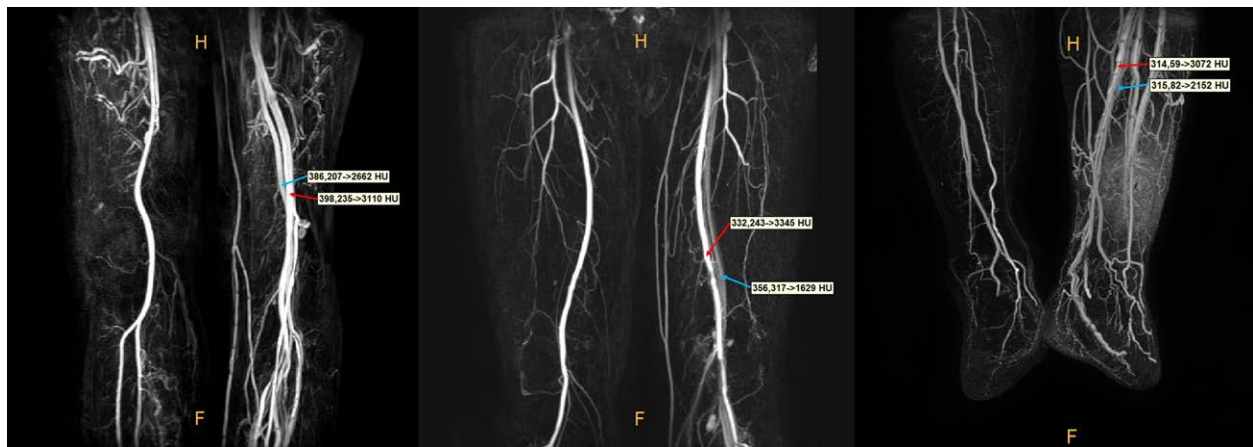
In our study, arterial occlusion frequently occurred among the elderly aged 65 years or older (*t*-score < 0.0001), diabetes mellitus (*t*-score = 0.004), hypertension (*t*-score = 0.007), and was significantly associated with low ABI (*P* < .0001). Many studies

reported that the risk of peripheral vascular disease increases in old age, hypertension, smoking history, diabetes, and hyperlipidemia,<sup>[2]</sup> with smoking, diabetes, and hypertension particularly serving as greater risk factors.<sup>[1,4]</sup> Nevertheless, contrary to the existing notion, smoking history had no effect on arterial patency in our study (*t*-score = 0.147). This is thought to be caused by the patients not responding properly to their smoking history. According to other studies, smoking is most strongly associated with arterial occlusion, where the incidence of PAD is 3 to 5 times higher among smokers compared to nonsmokers.<sup>[4]</sup> Diabetes mellitus is also highly associated with arterial occlusion, and PAD occurs 2 to 4 times more frequently in diabetic patients than in nondiabetic individuals.<sup>[3]</sup> Hyperlipidemia is also associated with atherosclerosis, and an increase of triglycerides and decrease of high-density lipoprotein cholesterol is known to be strongly associated with PAD. Also PAD incidence increases with increasing blood pressure.<sup>[4]</sup>

Factors that affect early VE were age 65 years or older (*t*-score = 0.001), no prior history of ulcer (*t*-score = 0.003), and no history of amputation (*t*-score = 0.048); notably, early VE was significantly associated with high hemoglobin/hematocrit level (*P* = .032/0.008) and low CRP level (*P* = .004). However, hypertension (*t*-score = 0.253) and diabetes mellitus (*t*-score = 0.797) that affect arterial patency were not significantly associated with early VE. From these results, we can conclude that VE related with healthier condition that had no ulcer or amputation history. As for the reason why it appears more prominent in the elderly, it is speculated that it is because it takes time for the collateral branches to develop. We confirmed that the factors inducing arterial occlusion was not same factors that cause early vein enhancement.

Advances of CT scanner technology have improved the resolution quality of vascular images,<sup>[22]</sup> and it is now possible to examine vascular patency and determine the direction of treatment based on these quality images.<sup>[23,24]</sup> Early deep vein or superficial vein enhancement commonly occur when scanning duration is prolonged or when patients have active inflammation, including those with uninfected ulcers. Considering the quick arteriovenous passage shown in angiography in some patients, early vein enhancement cannot be completely eliminated.<sup>[23]</sup> Nevertheless, these artifacts are eliminated through processing to get clear view, and they do not pose a problem in diagnosing arterial disease.<sup>[20]</sup> Early vein enhancement is accepted as a quick passage of the contrast medium caused by vasodilation resulting from elevated local blood circulation and hyperemia.<sup>[25]</sup> There is a normal physiological reaction manifested by inflammation. Such is the reaction of increased blood flow and increased vascular permeability.<sup>[26]</sup> Swelling and redness are caused by excessive leakage of fluid and inflammatory mediators. These are probably the factors that cause the veins to be early enhancement in the arterial phase.<sup>[27,28]</sup> Therefore, the appearance of early VE in CT can be related with response of increased blood flow.

This study has a few limitations. First, 145 patients at single hospital were enrolled in this study. Since the principles of CT are usually similar in other hospitals, similar results are expected to be achieved in other hospitals, but additional multicenter prospective studies will be needed. Second, most patients underwent percutaneous transluminal angioplasty when they were diagnosed with complete occlusion; however, there are no data on the effects of this procedure on early VE. Furthermore, we could not include this as an independent variable in our study because it was difficult to control, as blood flow could be obstructed again and revascularization injury can occur in some cases even after successful angioplasty.<sup>[29,30]</sup> Third, only those patients with wound images available were included in the study. Fourth, there was difficult to apply to patients with impaired kidney function or allergies to contrast agents. Recently, however, the author identified an interesting point: a similar phenomenon



**Figure 7.** Evaluation of arterial and venous enhancement in MRA. MRA has also seen similar results to CTAs. The red arrow means the brightness of the arteries, and the blue arrow means the brightness of the veins. Even the veins were better identified compared to CTA, which will require further research. CTA = computed tomographic angiography.

was confirmed when MRA was taken in patients who could not take contrast-enhanced CT (Fig. 7). Therefore, in the future, the MRA information will also be integrated for further research. Finally, there are no data on whether early VE disappears after the wound is healed because contrast-enhanced lower limb CTA cannot be performed simply as a follow-up test after the wound is healed, because doing so is costly and affects renal function. Additional studies are needed to identify the environments and mechanisms in which early VE occurs.

## 5. Conclusions

In conclusion, veins of ischemic limb that show early enhancement are suspected of being healthier and more responsive to inflammation than those that do not show early enhancement. This study is meaningful in that it showed that early VE, that has been considered an artifact in the past, could have significant clinical implications. Clinical progress can be predicted more accurately when early VE is examined in addition to the existing arterial assessment. VE can be easily examined during arterial assessment without an additional test, and it could be applied to numerous fields in the future, including vascular assessment prior to flap implantation. Also, it can be easily reproduced in other facilities that equipped with CT scan.

## References

- [1] Aronow H. Peripheral arterial disease in the elderly: recognition and management. *Am J Cardiovascular Drugs*. 2008;8:353–64.
- [2] Hirsch AT, Criqui MH, Treat-Jacobson D, et al. Peripheral arterial disease detection, awareness, and treatment in primary care. *J Am Med Assoc*. 2001;286:1317–24.
- [3] Matsi PJ, Manninen H, Laakso M, et al. Impact of risk factors on limb salvage after angioplasty in chronic critical lower limb ischemia. A prospective trial. *Angiology*. 1994;45:797–804.
- [4] Nowygrod R, Egorova N, Greco G, et al. Trends, complications, and mortality in peripheral vascular surgery. *J Vasc Surg*. 2006;43:205–16.
- [5] Orchard TJ, Strandness DE Jr. Assessment of peripheral vascular disease in diabetes. Report and recommendations of an international workshop sponsored by the American Diabetes and the American Heart Association. 1993;88:819–828.
- [6] Fleischmann D, Hallett RL, Rubin GD. CT angiography of peripheral arterial disease. *J Vascular Interventional Radiol*. 2006;17:3–26.
- [7] Vogt MT, Cauley JA, Newman AB, et al. Decreased ankle/arm pressure index and mortality in elderly woman. *J Am Med Association*. 1993;270:465–9.
- [8] Taylor GI, Palmer JH. The vascular territories (angiosomes) of the body: experimental study and clinical applications. *Br J Plastic Surg*. 1987;40:113–41.
- [9] Muntner P, Wildman RP, Reynolds K, et al. Relationship between HbA1c level and peripheral arterial disease. *Diabetes Care*. 2005;28:1981–7.
- [10] Hackam DG, Anand SS. Emerging risk factors for atherosclerotic vascular disease: a critical review of the evidence. *J Am Med Assoc*. 2003;290:932–40.
- [11] Armstrong DG, Lavery LA, Harkless LB. Validation of a diabetic wound classification system. The contribution of depth, infection, and ischemia to risk of amputation. *Diabetes Care*. 1998;21:855–9.
- [12] Jeon BJ, Choi HJ, Kang JS, et al. Comparison of five systems of classification of diabetic foot ulcers and predictive factors for amputation. *Int Wound J*. 2016;14:537–45.
- [13] Wallace A, Pershad Y, Saini A, et al. Computed tomography angiography evaluation of acute limb ischemia. *VASA*. 2019;48:57–64.
- [14] Al-Rudaini H, Han P, Liang H. Comparison between computed tomography angiography and digital subtraction angiography in critical lower limb ischemia. *Curr Med Imag Rev*. 2019;15:496–503.
- [15] Foley WD, Stonely T. CT angiography of the lower extremities. *Radiol Clin North Am*. 2010;48:367–96.
- [16] Gupta A, Obmann YC, Jordan M, et al. CT artifacts after contrast media injection in chest imaging: evaluation of post-processing algorithms, virtual monoenergetic images and their combination for artifact reduction. *Quantitative Imag Med Surg*. 2021;11:226–39.
- [17] Barrett JE, Keat N. Artifacts in CT: recognition and avoidance. *Radiographics*. 2004;24:1679–91.
- [18] Sasaki M, Honmou O, Radtke C, et al. Development of a middle cerebral artery occlusion model in the nonhuman primate and a safety study of i.v. infusion of human mesenchymal stem cells. *Public Library Sci One*. 2011;6:e26577.
- [19] Parthasarathy R, Kate M, Rempel JL, et al. Prognostic evaluation based on cortical vein score difference in stroke. *Stroke*. 2013;44:2748–54.
- [20] Berlin DA, Bakker J. Understanding venous return. *Intensive Care Med*. 2014;40:1564–6.
- [21] Brevetti G, Giugliano G, Brevetti L, et al. Inflammation in peripheral artery disease. *Circulation*. 2010;122:1862–75.
- [22] Soto JA, Munera F, Morales C, et al. Focal arterial injuries of the proximal extremities: Helical CT arteriography as the initial method of diagnosis. *Radiology*. 2001;218:188–94.
- [23] Rubin GD, Schmidt AJ, Logan LJ, et al. Multi-detector row CT angiography of lower extremity arterial inflow and runoff: Initial experience. *Radiology*. 2001;221:146–58.
- [24] Portugaller HR, Schoellnast H, Hausegger KA, et al. Multislice spiral CT angiography in peripheral arterial occlusive disease: a valuable tool in detecting significant arterial lumen narrowing? *Eur Radiol*. 2004;14:1681–7.
- [25] Milne EN. The significance of early venous filling during femoral arteriography. *Radiology*. 1967;88:513–8.

- [26] Harris N, Carter P, Lee SJ, et al. Association between blood flow and inflammatory state in a T-cell transfer model of inflammatory bowel disease in mice. *Inflammatory Bowel Disease*. 2010;16:776–782
- [27] Heyeraas KJ, Kvinnsland I. Tissue pressure and blood flow in pulpal inflammation. *Proc Finnish Dental Soc*. 1992;88:393–401.
- [28] McCarthy C, Gouloupoulou S, Webb R. Paying the toll for inflammation: Immunoreceptor-mediated vascular dysfunction in hypertension, Vasculopathy, inflammation, and blood flow in leg ulcers of patients with sickle cell anemia. *Hypertension*. 2019;73:514–21.
- [29] Carden DL, Granger DN. Pathophysiology of ischaemia-reperfusion injury. *J Pathol*. 2000;190:255–66.
- [30] Heilmann C, Schmoor C, Siepe M, et al. Controlled reperfusion versus conventional treatment of the acutely ischemic limb: results of a randomized, open-label, multicenter trial. *Circulation*. 2013;6:417–27.