



# Bipolar Hemiarthroplasty in Unstable Intertrochanteric Fractures with an Effective Wiring Technique

Jae-Hwi Nho, MD, Gi-Won Seo, MD, Tae Wook Kang, MD,  
Byung-Woong Jang, MD\*, Jong-Seok Park, MD†, You-Sung Suh, MD

*Department of Orthopaedic Surgery, Soonchunhyang University Hospital Seoul, Seoul, Korea*  
*Department of Orthopaedic Surgery, Soonchunhyang University Hospital Gumi, Gumi, Korea\**  
*Department of Orthopaedic Surgery, Soonchunhyang University Hospital Cheonan, Cheonan, Korea†*

**Purpose:** Bipolar hemiarthroplasty has recently been acknowledged as an effective option for treatment of unstable intertrochanteric fracture. Trochanteric fragment nonunion can cause postoperative weakness of the abductor muscle and dislocation; therefore, reduction and fixation of the fragment is essential. The purpose of this study was to perform an evaluation and analysis of the outcomes of bipolar hemiarthroplasty using a useful wiring technique for management of unstable intertrochanteric fractures.

**Materials and Methods:** A total of 217 patients who underwent bipolar hemiarthroplasty using a cementless stem and a wiring technique for management of unstable intertrochanteric femoral fractures (AO/OTA classification 31-A2) at our hospital from January 2017 to December 2020 were included in this study. Evaluation of clinical outcomes was performed using the Harris hip score (HHS) and the ambulatory capacity reported by patients was classified according to Koval stage at six months postoperatively. Evaluation of radiologic outcomes for subsidence, breakage of wiring, and loosening was also performed using plain radiographs at six months postoperatively.

**Results:** Among 217 patients, five patients died during the follow-up period as a result of problems unrelated to the operation. The mean HHS was  $75 \pm 12$  and the mean Koval category before the injury was  $2.5 \pm 1.8$ . A broken wire was detected around the greater trochanter and lesser trochanter in 25 patients (11.5%). The mean distance of stem subsidence was  $2.2 \pm 1.7$  mm.

**Conclusion:** Our wiring fixation technique can be regarded as an effective additional surgical option for fixation of trochanteric fracture fragments during performance of bipolar hemiarthroplasty.

**Key Words:** Intertrochanter fracture, Wiring technique, Bipolar hemiarthroplasty, Cementless stem

**Submitted:** October 12, 2022 **1st revision:** December 22, 2022  
**2nd revision:** January 30, 2023 **Final acceptance:** February 1, 2023  
**Address reprint request to**

**Gi-Won Seo, MD**

(<https://orcid.org/0000-0003-2531-9707>)

Department of Orthopaedic Surgery, Soonchunhyang University  
Hospital Seoul, 59 Daesagwan-ro, Yongsan-gu, Seoul 04401, Korea

**TEL:** +82-2-709-9250

**E-mail:** 102980@schmc.ac.kr

This is an Open Access article distributed under the terms of the Creative Commons Attribution Non-Commercial License (<http://creativecommons.org/licenses/by-nc/4.0>) which permits unrestricted non-commercial use, distribution, and reproduction in any medium, provided the original work is properly cited.

## INTRODUCTION

Intertrochanteric fractures are among the most common and fatal fractures affecting elderly patients. The prevalence of intertrochanteric fractures in Korea was 26.8 per 100,000 people in 2010. Along with aging of the population, an increase in the number of hip fractures to approximately 4.5 million per year worldwide is expected by 2050. Consequently, the number of unstable intertrochanteric fractures is also increasing<sup>1-5</sup>.

Osteosynthesis has been widely administered for treatment of intertrochanteric fractures, which are metaphyseal fractures. However, internal fixation is technically difficult and use of the current treatment often results in failure to maintain stable fixation in this type of fracture; thus treatment of unstable intertrochanteric fracture in osteoporotic elderly patients remains a challenge<sup>6</sup>. In addition, several studies have reported on complications of osteosynthesis such as nonunion or cut-out<sup>7,8</sup>. With aging of the population, morbidity resulting from intertrochanteric fractures has increased and previous studies have reported on the importance of early ambulation and a shortened period of hospitalization<sup>3,9</sup>.

Because bipolar hemiarthroplasty can enable early full weight-bearing and functional rehabilitation, it has recently been acknowledged as an effective option for treatment of intertrochanteric fracture<sup>10-12</sup>. In addition, because it enables earlier mobilization compared to osteosynthesis, use of bipolar hemiarthroplasty could lead to a significant reduction in the incidence of postoperative cerebrovascular accidents<sup>13</sup>.

Many previous studies have reported on the importance of accomplishing reduction and fixation of trochanteric fragments during performance of bipolar hemiarthroplasty because nonunion of trochanteric fragments can cause postoperative weakness of the abductor muscle and dislocation<sup>14-16</sup>.

Therefore, in this study, a cementless stem was utilized in performance of bipolar hemiarthroplasty for treatment of intertrochanteric fractures and fixation of the trochanteric fragments was performed using a wiring technique. The purpose of this study was to perform an evaluation and analysis of the outcomes of bipolar hemiarthroplasty using an effective wiring technique for management of unstable intertrochanteric fractures in our hospital.

## MATERIALS AND METHODS

### 1. Materials

This retrospective observational study was approved by the Institutional Review Board (IRB) of Soonchunhyang University Hospital Seoul (No. SCHUH 2023-05-016 2), and the informed consent was waived by the IRB. Patients who underwent bipolar hemiarthroplasty using a cementless stem (Bencox II STEM; Corentec; manufactured from titanium) and a wiring technique for treatment of unstable intertrochanteric femoral fractures (AO/OTA classification 31-A2) at Soonchunhyang University Hospital Seoul from January 2017 to December 2020 were included. Patients who were available for follow-up for at least six months and were older than 65 years were included. Patients with loss of follow-up were excluded. All operations were performed by one senior surgeon. These patients were evaluated for clinical and radiologic outcomes at six months postoperatively.

Evaluation of clinical outcomes was performed using the Harris hip score (HHS) and the ambulatory capacity reported by patients was classified according to Koval stage. Evaluation of radiologic outcome for subsidence, breakage of wiring, and loosening was also performed using postoperative plain radiographs.

Descriptive statistics were performed. All analyses were performed using IBM SPSS Statistics (ver. 22.0; IBM).

### 2. Surgical Procedure

#### 1) Posterolateral approach

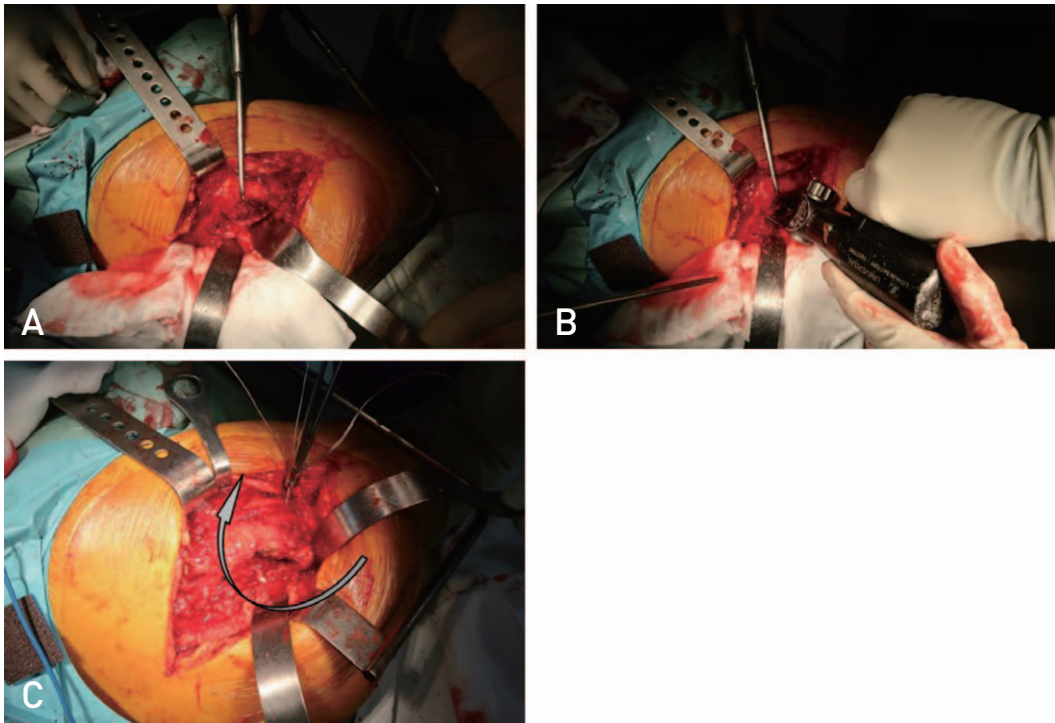
All operations were performed in a lateral decubitus position using the posterolateral approach; Bencox II STEM (Corentec) bipolar cups and cementless femoral stems were used in all patients (Fig. 1A, B).

#### 2) Restoration of the diaphysis

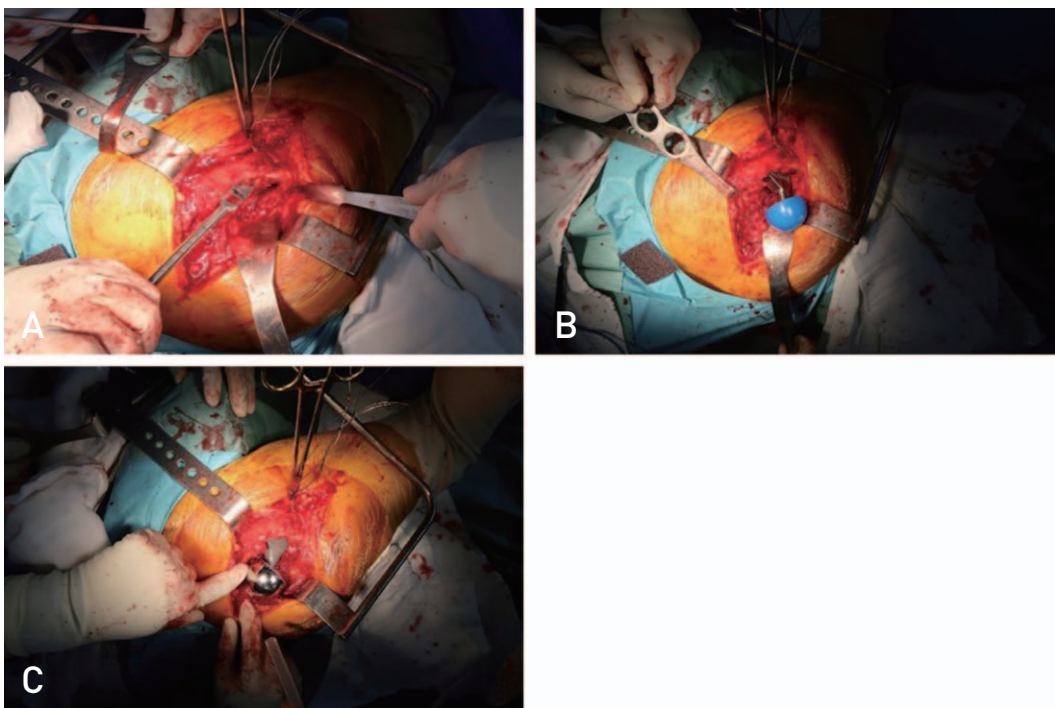
Attachment of the lesser trochanter and fracture fragment was performed prior to rasping and stem insertion. Cable fixation or lesser grip fixation was then used in the diaphysis around the lesser trochanter (Fig. 1C).

#### 3) Femoral stem insertion

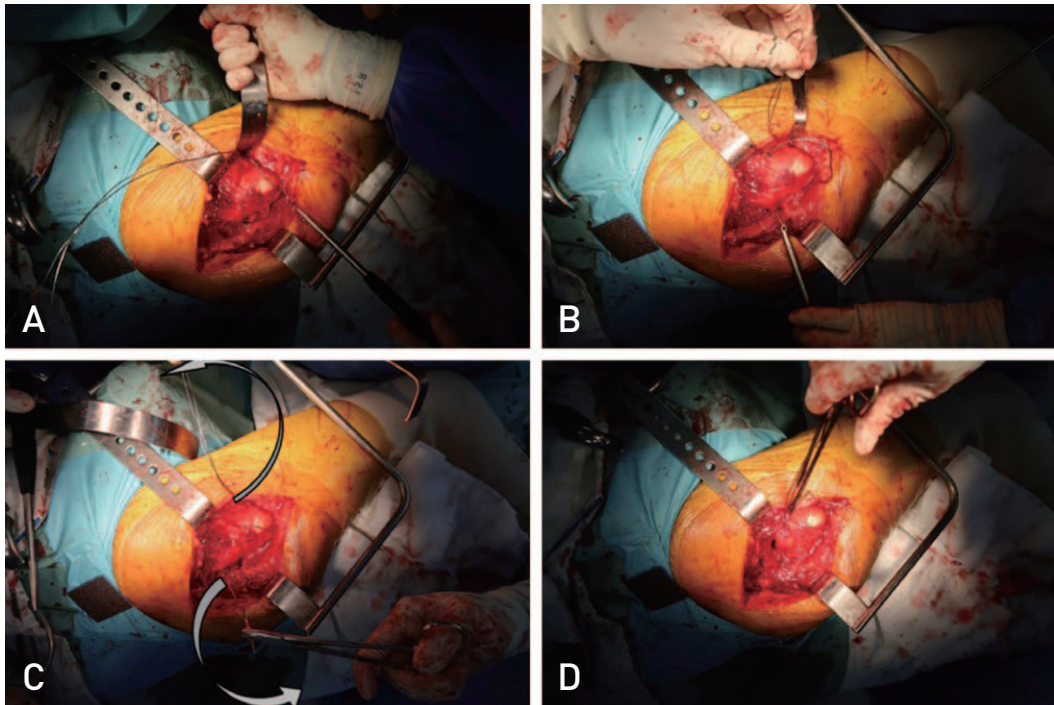
After restoration of the diaphysis, the femoral canal was gradually prepared using a rasp, which was used for conduct of stem trials to determine the stem size with appropriate stability and leg length (Fig. 2A, B). A temporary reduc-



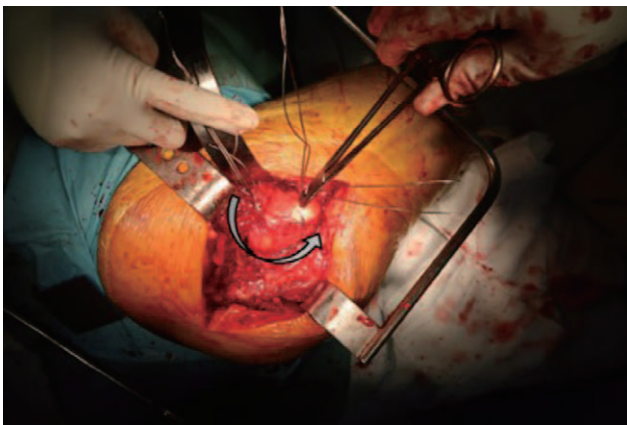
**Fig. 1.** (A) Posterolateral approach was used—pyriformis, short external rotator, and quadratus femoris were dissected from tendinous insertion. (B) Neck cutting without dislocation of the femoral head to prevent additional injury of the diaphysis and lesser trochanter. The femoral head can be removed by corkscrew after neck cutting without head dislocation. (C) Restoration of the diaphysis. Cable fixation or lesser grip fixation were used in the diaphysis around the lesser trochanter to prevent diaphyseal fracture extension.



**Fig. 2.** (A-C) Femoral stem insertion - Femoral canal preparation by rasping - Insertion of an appropriate stem.



**Fig. 3. (A-D)** Greater trochanter fixation with figure 8 configuration; from lesser trochanter to greater trochanter using a double wire for axial and sagittal displacement.



**Fig. 4.** Coronal split augmentation. Double wire fixation around the greater trochanter.

tion was then performed using the stem trial and cup trial, and intraoperative assessment of the true leg-length discrepancy was performed (Fig. 2C).

#### 4) Greater trochanter fixation with figure 8 configuration

The greater trochanter fragments were attached and fixed with wires. After folding the 18-gauge stainless steel wires into double rows, the wire was passed through the lesser trochanter, the medial side of the proximal femur, and the

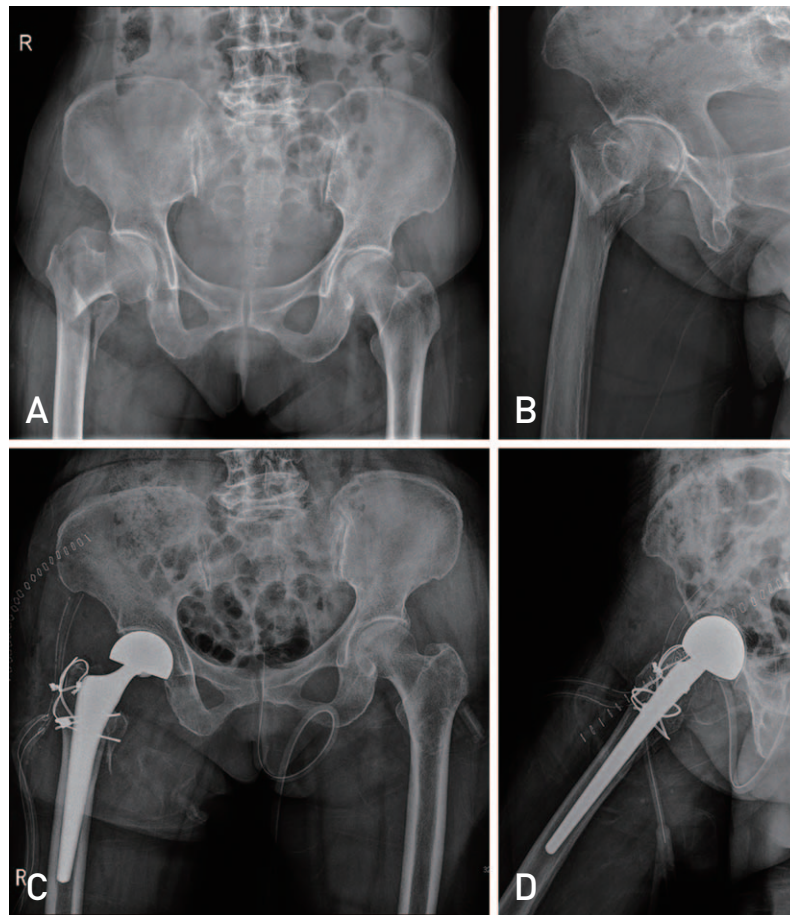
iliopsoas muscle using a wire passer (Fig. 3A, B). The gluteus medius muscle attached to the greater trochanteric fragment was then passed in a figure 8 configuration and fixation was performed using a tension band wiring technique (Fig. 3C, D).

#### 5) Coronal split augmentation

In addition, the greater trochanter was fixed with double wires in order to obtain coronal split augmentation (Fig. 4, 5A, B, 6).

### 3. Postoperative Management

All patients were encouraged to walk using a walker with tolerable weight bearing on the operative side after the postoperative second day. The patients performed walker ambulation as far as possible after removal of the drain on the second day. Patients with severe postoperative pain started ambulation after the second day; however, 2% of these patients did not perform ambulation until total stitch out. To prevent thromboembolism, low-molecular heparin was administered, and patients wore antiembolic stockings and an intermittent pneumatic pump was applied in the bed. Follow-up evaluations were performed at postoperative six months.



**Fig. 5.** (A, B) Preoperative plain radiograph of a right femur intertrochanteric fracture AO/OTA classification type 31-A2. (C, D) Immediate postoperative plain radiograph showing bipolar hemiarthroplasty using the wiring technique.

## RESULTS

In all 217 cases, bipolar hemiarthroplasty was performed using a cementless stem and the wiring technique (Table 1). Despite concerns about infection caused by wiring, no cases of infection were detected. In addition, none of the patients developed intraoperative complications. However, five patients (2.3%, 5/217) died during the follow-up period as a result of problems unrelated to the operation. The mean hospital stay was 10.7 days (range, 7-20 days). There was no readmission within 30 days due to dislocation or infection.

Assessment of clinical outcomes was performed at postoperative six months using the HHS and Koval category. Evaluation using the HHS was performed at pre-trauma and postoperative six months. The mean HHS decreased from  $83 \pm 11$  at pre-trauma to  $75 \pm 12$  at postoperative six months follow-up (Table 2).

Walking ability was evaluated according to the Koval categories at pre-trauma and postoperative six months. The

mean Koval categories showed a slight increase from pre-traumatic  $1.45 \pm 1.2$  to  $2.5 \pm 1.8$  at postoperative six months. Almost all of the patients were able to walk with a cane or walker at postoperative six months.

Analysis of radiologic results was performed at postoperative six months in all patients. There were no cases of aseptic loosening or osteolysis of the stem or dislocation or nonunion of the greater trochanter.

A broken wire was detected around the greater trochanter and lesser trochanter in 25 patients (11.5%). However, revision surgery due to complications resulting from wire breakage was not performed in any case. None of the patients complained of bursitis related to a broken wire, such as swelling or pain and there were no cases of loss of reduction or loss of fixation, requiring revision surgery.

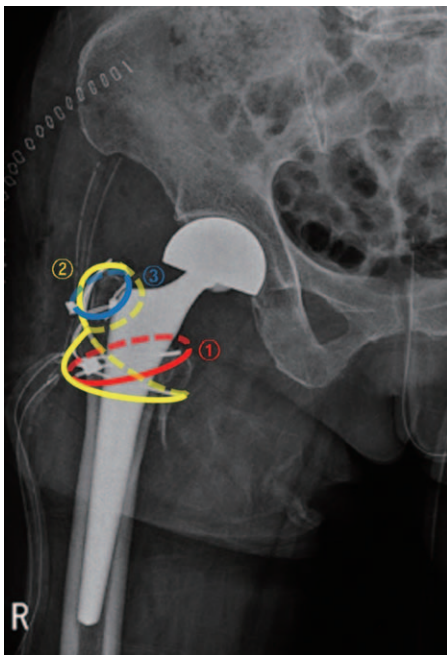
Evaluation of stem subsidence was based on the immediate postoperative radiograph and the follow-up radiograph. The subsidence of the stem was observed in seven patients (3.2%) on postoperative radiographs taken at six months. The mean distance of stem subsidence was  $2.2 \pm 1.7$  mm.

However, in all cases, the subsidences were not progressive, thus revision surgery was not performed in any case.

Fortunately, there were no severe complications, including pulmonary embolism, infarction, and myocardial infarction caused by thrombus during the hospital stay.

## DISCUSSION

The risk factors for failure of internal fixation in management of unstable femoral intertrochanteric fracture are: 1) loss of the medial buttress, 2) markedly displaced fractures, 3) reverse obliquity fractures, 4) severe osteoporosis, 5) comminution at the fracture site<sup>17</sup>. According to AO/OTA, 31-A2 is classified as a fracture with comminution of the fracture site, which is an unstable fracture. This study includ-



**Fig. 6.** The sequence of the trochanter wiring technique. ① Diaphysis restoration by lesser grip fixation around the lesser trochanter. ② Figure 8 configuration fixation from lesser trochanter to greater trochanter. ③ Wire fixation around the greater trochanter to coronal split augmentation.

ed patients classified as 31-A2.

With the increasing life expectancy of the elderly population, the prevalence of intertrochanteric fractures is increasing and, consequently, the demand for surgery is also increasing. From 2010 to 2019, the number of patients with intertrochanteric fractures has shown a steady increase, reaching approximately 35,000 per year in South Korea. Although intertrochanteric fracture is regarded as a lower energy injury in the elderly, there is a high number of unstable fractures because the fracture type is often accompanied by comminution<sup>18</sup>. Accordingly, many ongoing studies on clinically effective and cost-effective treatment are being conducted<sup>1,4,19</sup>. However, treatment of unstable intertrochanteric fractures in the elderly has always been controversial.

Several studies have recommended the use of a proximal femoral nail for treatment of unstable femoral intertrochanteric fractures<sup>19,22</sup>. However, more satisfactory results have been reported with the use of bipolar hemiarthroplasty in treatment of unstable intertrochanteric fractures compared with

**Table 1.** Demographic Data of Patients

Parameter	Value
No. of patients	217
Age (yr)	85.4±6.7
Female	86.9±6.4
Male	78.6±8.7
Sex	
Female	192 (88.5)
Male	25 (11.5)
Fracture type (AO/OTA 31-A2)	217
BMI (kg/m <sup>2</sup> )	26.8±3.2
ASA scales	2.3±0.8
BMD (L spine T-score)	-2.7±0.3
Hypertension	189 (87.1)
Diabetics	175 (80.6)

Values are presented as number only, mean±standard deviation, or number (%).

BMI: body mass index, ASA: American Society of Anaesthesiologists, BMD: bone mineral density.

**Table 2.** Clinical Outcome at Pre-Trauma and Postoperative 6 Months

Parameter	Pre-trauma	Postoperative 6 months
Harris hip score	83±11	75±12
Koval category	1.45±1.2	2.5±1.8
Wire breakage	-	25/217 (11.5)
Stem subsidence	-	7/217 (3.2)
Stem subsidence (mm)	-	2.2±1.7

Values are presented as mean±standard deviation or number (%).

a proximal femoral nail<sup>23</sup>). A lower reoperation rate and lower decrement rate of walking ability has been reported with use of bipolar hemiarthroplasty compared to internal fixation after surgery for treatment of unstable intertrochanteric fracture in elderly patients<sup>24</sup>.

In a study comparing the curative effect of PFNA (proximal femoral nail antirotation) and cementless bipolar hemiarthroplasty, a significantly longer operation time and more intraoperative blood loss and blood transfusion was reported for bipolar hemiarthroplasty compared with internal fixation. However, the average time of postoperative weight-bearing training was significantly shorter compared with the internal fixation group<sup>12,25</sup>. In addition, the findings of a systematic review demonstrated that use of arthroplasty in treatment of unstable intertrochanteric femoral fracture can result in superior functional outcomes, particularly in earlier mobilization, compared to internal fixation<sup>26</sup>. In addition, the loss of the pre-fracture basic mobility level upon acute hospital discharge showed an association with increased 30-day post-discharge mortality and readmission after a first-time hip fracture<sup>27</sup>. Considering these findings, compared to internal fixation, bipolar hemiarthroplasty can be regarded as an effective treatment option.

There are three technical challenges in performance of arthroplasty for treatment of unstable intertrochanteric fractures<sup>18</sup>. The first is the difficulty of leg length restoration. Before rasping, fixation of the proximal bone fragments and lesser tuberosity was performed using cables or wires. As a result, the lesser tuberosity was reduced to some extent, which was helpful in measurement of the leg length. In addition, measurement of the contralateral hip was performed to determine the head-lesser trochanteric distance, and evaluation of the soft tissue tension during the operation and the stability of hip motion after the reduction during the operation was performed.

Second, the difficulty of attaining initial stability. In this study, the method used for fixation of proximal fragments and lesser tuberosity before rasping provides the advantage of attainment of a more stable stem fixation. Fixation of proximal fragments and lesser tuberosity resulted in achievement of a more stable initial stability by locating a stable position by application of internal and external pressure during rasping.

Third, the difficulty associated with reduction and fixation of the greater or lesser tuberosity. In particular, fixation of the greater tuberosity is important for preservation of the abductor mechanism. There is a profound association between weakness of the abductor and a displaced greater trochanter fragment and fragment displacement greater than 2 cm may

result in significant weakness of the abductor. In addition, it could result in postoperative dislocation<sup>28</sup>. Compared with other methods, fixation is helpful when using the tension band wiring method as a method for fixation of the greater trochanter<sup>29</sup>. In this study, fixation of the greater tuberosity was performed in the same way, and wiring was added separately for the greater trochanter with coronal splitting. Good results were obtained with appropriate reduction and fixation. Displacement of the greater and lesser trochanter can cause weakness of the abductor muscle, psoas, and flexor muscle, which can result in gait disturbance after surgery. Therefore, strong fixation with strong wiring is important, and enables early ambulation. Although a grip plate might be used to attain rigid fixation, use of this technique has been associated with complications of nonunion and symptoms of irritation, suggesting that wiring is preferable.

Lower limb length discrepancy was observed on plain radiographs of the intertrochanteric fracture at 12 months postoperatively in the bipolar hemiarthroplasty group compared with the internal fixation group<sup>4</sup>. Stem subsidence was also assessed on a radiograph at six months postoperatively, and the mean distance was  $2.2 \pm 1.7$  mm, indicating relatively satisfactory results. In addition, there were no cases of nonunion or reduction loss of fixation. This finding suggested that our wiring technique is effective for maintenance of the reduction of trochanteric fragments.

This study has several limitations; it was a retrospective study, and there is a limitation in that the follow-up period was six-months, and performance of a statistical comparison was not possible due to lack of a control group. In addition, there may have been selection bias in the overall outcomes due to loss of follow-up.

## CONCLUSION

In our study, good results were obtained with performance of bipolar surgery for treatment of unstable intertrochanteric fractures using our wiring technique, confirming its potential as a treatment option for this type of fracture. Therefore, use of appropriate wiring techniques is important for achievement of favorable clinical outcomes.

## FUNDING

This work was supported by the Soonchunhyang University Research Fund.

## CONFLICT OF INTEREST

The authors declare that there is no potential conflict of interest relevant to this article.

## REFERENCES

- Mundi S, Pindiprolu B, Simunovic N, Bhandari M. *Similar mortality rates in hip fracture patients over the past 31 years.* *Acta Orthop.* 2014;85:54-9. <https://doi.org/10.3109/17453674.2013.878831>
- Yoon BH, Lee YK, Kim SC, Kim SH, Ha YC, Koo KH. *Epidemiology of proximal femoral fractures in South Korea.* *Arch Osteoporos.* 2013;8:157. <https://doi.org/10.1007/s11657-013-0157-9>
- Cooper C, Cole ZA, Holroyd CR, et al. *Secular trends in the incidence of hip and other osteoporotic fractures.* *Osteoporos Int.* 2011;22:1277-88. <https://doi.org/10.1007/s00198-011-1601-6>
- Suh YS, Nho JH, Kim SM, Hong S, Choi HS, Park JS. *Clinical and radiologic outcomes among bipolar hemiarthroplasty, compression hip screw and proximal femur nail antirotation in treating comminuted intertrochanteric fractures.* *Hip Pelvis.* 2015;27:30-5. <https://doi.org/10.5371/hp.2015.27.1.30>
- Suh YS, Nho JH, Seo J, Jang BW, Park JS. *Hip fracture surgery without transfusion in patients with hemoglobin less than 10 g/dL.* *Clin Orthop Surg.* 2021;13:30-6. <https://doi.org/10.4055/cios20070>
- Zhang B, Chiu KY, Wang M. *Hip arthroplasty for failed internal fixation of intertrochanteric fractures.* *J Arthroplasty.* 2004;19:329-33. <https://doi.org/10.1016/j.arth.2003.10.010>
- Chirodian N, Arch B, Parker MJ. *Sliding hip screw fixation of trochanteric hip fractures: outcome of 1024 procedures.* *Injury.* 2005;36:793-800. <https://doi.org/10.1016/j.injury.2005.01.017>
- Wessels JO, Bjarnesen MP, Erichsen JL, Palm H, Gundtoft PH, Viberg B. *Sliding hip screw vs intramedullary nail for AO/OTA31A1-A3: a systematic review and meta-analysis.* *Injury.* 2022;53:1149-59. <https://doi.org/10.1016/j.injury.2021.12.034>
- Stavrou ZP, Erginousakis DA, Loizides AA, Tzevelekos SA, Papagiannakos KJ. *Mortality and rehabilitation following hip fracture. A study of 202 elderly patients.* *Acta Orthop Scand Suppl.* 1997;275:89-91. <https://doi.org/10.1080/17453674.1997.11744754>
- Khan RJ, MacDowell A, Crossman P, et al. *Cemented or uncemented hemiarthroplasty for displaced intracapsular femoral neck fractures.* *Int Orthop.* 2002;26:229-32. <https://doi.org/10.1007/s00264-002-0356-2>
- Park JH, Chung YY, Baek SN, Park TG. *Hemiarthroplasty through direct anterior approach for unstable femoral intertrochanteric fractures in the elderly: analysis of early cases.* *Hip Pelvis.* 2022;34:79-86. <https://doi.org/10.5371/hp.2022.34.2.79>
- Zhou S, Liu J, Zhen P, et al. *Proximal femoral nail anti-rotation versus cementless bipolar hemiarthroplasty for unstable femoral intertrochanteric fracture in the elderly: a retrospective study.* *BMC Musculoskelet Disord.* 2019;20:500. <https://doi.org/10.1186/s12891-019-2793-8>
- Dubin J, Atzmon R, Feldman V, et al. *Bipolar hemiarthroplasty may reduce cerebrovascular accidents and improve early weight-bearing in the elderly after femoral neck fracture.* *Medicine (Baltimore).* 2022;101:e28635. <https://doi.org/10.1097/MD.00000000000028635>
- Abdelkhalek M, Ali AM, Abdelwahab M. *Cemented bipolar hemiarthroplasty with a cerclage cable technique for unstable intertrochanteric hip fractures in elderly patients.* *Eur J Orthop Surg Traumatol.* 2013;23:443-8. <https://doi.org/10.1007/s00590-012-1006-z>
- Grimrud C, Monzon RJ, Richman J, Ries MD. *Cemented hip arthroplasty with a novel cerclage cable technique for unstable intertrochanteric hip fractures.* *J Arthroplasty.* 2005;20:337-43. <https://doi.org/10.1016/j.arth.2004.04.017>
- McGrory BJ, Morrey BF, Cahalan TD, An KN, Cabanela ME. *Effect of femoral offset on range of motion and abductor muscle strength after total hip arthroplasty.* *J Bone Joint Surg Br.* 1995;77:865-9. <https://doi.org/10.1302/0301-620X.77B6.7593096>
- Lichtblau S. *The unstable intertrochanteric hip fracture.* *Orthopedics.* 2008;31:792-7. <https://doi.org/10.3928/01477447-20080801-15>
- Lee JM, Cho Y, Kim J, Kim DW. *Wiring techniques for the fixation of trochanteric fragments during bipolar hemiarthroplasty for femoral intertrochanteric fracture: clinical study and technical note.* *Hip Pelvis.* 2017;29:44-53. <https://doi.org/10.5371/hp.2017.29.1.44>
- Ruecker AH, Rupprecht M, Gruber M, et al. *The treatment of intertrochanteric fractures: results using an intramedullary nail with integrated cephalocervical screws and linear compression.* *J Orthop Trauma.* 2009;23:22-30. <https://doi.org/10.1097/BOT.0b013e31819211b2> Erratum in: *J Orthop Trauma.* 2009;23:378.
- Kim SH, Meehan JP, Lee MA. *Surgical treatment of trochanteric and cervical hip fractures in the United States: 2000-2009.* *J Arthroplasty.* 2013;28:1386-90. <https://doi.org/10.1016/j.arth.2012.09.007>
- Kim KC, Shin HK, Son KM, Ko CS. *The treatment of unstable intertrochanteric fractures of femur: comparison between proximal femoral nail and dynamic hip screw.* *J Korean Fract Soc.* 2005;18:369-74. <https://doi.org/10.12671/jkfs.2005.18.4.369>
- Singh V, Sharam S, Shandilya A. *Functional & radiological outcome of fracture intertrochanter femur treated by Trochanter Femoral Nail.* *Orthop JMPC.* 2017;23:36-41. <https://doi.org/10.5281/zenodo.3970585>
- Chu X, Liu F, Huang J, Chen L, Li J, Tong P. *Good short-term outcome of arthroplasty with Wagner SL implants for unstable intertrochanteric osteoporotic fractures.* *J Arthroplasty.* 2014;29:605-8. <https://doi.org/10.1016/j.arth.2013.07.029>
- Kim JW, Shon HC, Song SH, Lee YK, Koo KH, Ha YC. *Reoperation rate, mortality and ambulatory ability after internal fixation versus hemiarthroplasty for unstable intertrochanteric fractures in elderly patients: a study on Korean Hip Fracture Registry.* *Arch Orthop Trauma Surg.* 2020;140:1611-8. <https://doi.org/10.1007/s00402-020-03345-2>
- Tang P, Hu F, Shen J, Zhang L, Zhang L. *Proximal femoral nail antirotation versus hemiarthroplasty: a study for the treatment of intertrochanteric fractures.* *Injury.* 2012;43:876-81. <https://doi.org/10.1016/j.injury.2011.11.008>
- Yoo JI, Ha YC, Lim JY, Kang H, Yoon BH, Kim H. *Early*



- rehabilitation in elderly after arthroplasty versus internal fixation for unstable intertrochanteric fractures of femur: systematic review and meta-analysis. J Korean Med Sci. 2017;32:858-67. <https://doi.org/10.3346/jkms.2017.32.5.858>*
27. Kristensen MT, Öztürk B, Röck ND, Ingeman A, Palm H, Pedersen AB. *Regaining pre-fracture basic mobility status after hip fracture and association with post-discharge mortality and readmission-a nationwide register study in Denmark. Age Ageing. 2019;48:278-84. <https://doi.org/10.1093/ageing/afy185>*
28. Amstutz HC, Mai LL, Schmidt I. *Results of interlocking wire trochanteric reattachment and technique refinements to prevent complications following total hip arthroplasty. Clin Orthop Relat Res. 1984;(183):82-9. <https://doi.org/10.1097/00003086-198403000-00015>*
29. Suh YS, Choi SW, Park JS, Yim SJ, Shin BJ. *Comparison between the methods for fixation of greater trochanteric fragment in cemented bipolar hemiarthroplasty for unstable intertrochanteric fracture. J Korean Hip Soc. 2008;20:104-9. <https://doi.org/10.5371/jkhs.2008.20.2.104>*