

# Visual Prognostic Value of Optical Coherence Tomography and Photopic Negative Response in Chiasmal Compression

Chan Hee Moon,<sup>1</sup> Sun Chul Hwang,<sup>2</sup> Bum-Tae Kim,<sup>2</sup> Young-Hoon Ohn,<sup>1</sup> and Tae Kwann Park<sup>1</sup>

**PURPOSE.** To investigate the potential of the optical coherence tomography (OCT) measurement of retinal nerve fiber layer (RNFL) thickness and ganglion cell complex (GCC) area and photopic negative response (PhNR) for predicting postoperative visual outcome in chiasmal compression, prospectively.

**METHODS.** Eighteen eyes of 18 patients undergoing chiasmal decompression surgery were prospectively assessed before, and 3 months after surgery with standard automated perimetry (SAP), OCT, and PhNR. Preoperative measurements were compared with 20 eyes of 20 age-matched controls. Spearman's correlation and regression analyses were conducted to evaluate the relationship between preoperative RNFL thickness, GCC area, PhNR/b-wave amplitude ratio, postoperative mean deviation (MD) and temporal visual field sensitivity (1/Lambert).

**RESULTS.** Preoperative measurements of RNFL thickness, GCC area, and PhNR/b-wave amplitude ratio were reduced significantly in patients compared with normal controls. Preoperative RNFL thickness of the temporal quadrant, GCC area, and PhNR/b-wave amplitude ratio were correlated significantly with postoperative MD and temporal visual field sensitivity (1/Lambert).

**CONCLUSIONS.** An eye with the more demonstrable structural deterioration, as shown by reduced RNFL thickness and GCC area, and retinal ganglion cell dysfunction as shown by decreased PhNR/b-wave amplitude ratio was associated with the worse visual fields outcome. RNFL thickness and GCC area measurements using OCT and PhNR/b-wave amplitude ratio could be a useful prognostic indicator in the preoperative assessment of chiasmal compression. (*Invest Ophthalmol Vis Sci.* 2011;52:8527–8533) DOI:10.1167/iovs.11-8034

Compression of the optic chiasm by tumors such as pituitary adenoma can lead to compromised visual function. The degree of postoperative recovery is thought to depend in part on the degree of structural and functional damages involving retrograde degeneration to retinal ganglion cells and their axon.<sup>1–4</sup>

Optical coherence tomography (OCT) is a noninvasive technique that allows cross-sectional imaging of the retina and

quantifies the thickness of the retinal nerve fiber layer (RNFL) around the optic nerve head. Moreover, the recently developed spectral-domain OCT (SD-OCT) acquires images more rapidly than time-domain OCT (TD-OCT) systems, allowing for much higher axial resolution and enabling selective measurement of the retinal layer. A number of studies have demonstrated that OCT is able to identify RNFL loss in eyes with band atrophy caused by chiasmal compression. The degree of RNFL thickness reduction has been shown to correlate with visual field defects.<sup>5–9</sup>

The photopic negative response (PhNR) is a negative wave that follows the photopic b-wave. It originates from the activity of retinal ganglion cells (RGCs) and their axons, which receive signals from cones.<sup>10,11</sup> Evidence has been accumulating that PhNR can be used to evaluate the functional condition of the neurons in the inner retina of patients with optic nerve disease.<sup>12–18</sup> However, previous studies have been cross-sectional and retrospective and have investigated the PhNR as a functional indicator in compressive optic neuropathy.<sup>17,18</sup> This study was the first attempt to clarify the prognostic value of the PhNR in the preoperative assessment of chiasmal compression.

The aim of the present study was to ascertain the potential of the OCT measurement of RNFL thickness and ganglion cell complex (GCC) area and PhNR for predicting postoperative visual outcome in chiasmal compression, prospectively.

## METHODS

### Subjects

Twenty consecutive patients diagnosed with chiasmal compression syndrome were prospectively recruited from the Ophthalmology and Neurosurgery Departments in our institution, between January 1, 2010 and March 15, 2011. The research adhered to the tenets of the Declaration of Helsinki. The institutional review board had approved the research and informed consent had been obtained.

Inclusion criteria were chiasmal compressive lesion confirmed by magnetic resonance imaging (MRI), with preoperative visual field (VF) impairment as determined by standard automated perimetry (SAP) using a visual field analyzer (Humphrey, Carl Zeiss Meditec, Dublin, CA), and underwent transphenoidal or transcranial surgery. The one eye with the lesser VF defect of each patient was selected for analysis.

In the preoperative assessment, all patients underwent a complete ophthalmic examination including visual acuity (VA), intraocular pressure (IOP), refraction, slit lamp biomicroscopy, gonioscopy, dilated stereoscopic fundus examination, SAP, OCT, and PhNR. At three months after surgery, the same examination was conducted.

Exclusion criteria were: any previous treatment including radiotherapy or medical treatment; any anterior segment, retinal, posterior segment, or optic nerve disease other than compressive optic neuropathy; a history of diabetes or any other systemic illness that may affect the retina and optic nerve; an unreliable VF testing >20% false positive,

From the Departments of <sup>1</sup>Ophthalmology and <sup>2</sup>Neurosurgery, Soonchunhyang University College of Medicine, Bucheon Hospital, Bucheon, Korea.

Submitted for publication June 12, 2011; revised September 1, 2011; accepted September 19, 2011.

Disclosure: C.H. Moon, None; S.C. Hwang, None; B.-T. Kim, None; Y.-H. Ohn, None; T.K. Park, None

Corresponding author: Tae Kwann Park, Department of Ophthalmology, Soonchunhyang University College of Medicine, Bucheon Hospital, #1174 Jung-dong, Wonmi-gu, Bucheon 420-767, Korea; tkpark@schmc.ac.kr.

false negative, or fixation loss; a spherical refractive error outside the range of  $\pm 5$  diopters (D); and postoperative complications including intracranial hemorrhage, cerebral edema, and further surgery for treatment of complications or tumor recurrence.

Eighteen eyes of 18 patients who met the inclusion criteria were included in the analysis. Two patients did not meet the inclusion criteria due to incomplete resection of a tumor in one patient and intracranial hemorrhage after surgery in one patient.

Twenty eyes of 20 age-matched controls had no history of chronic ocular or systemic disease and no other pathologic features in complete ophthalmic examination. Examinations including SAP, OCT, and PhNR were conducted identically for each patient.

### Brain Imaging

MRI was performed before and 3 months after surgery. Compression of the anterior visual pathway was confirmed before surgery. Tumor size was evaluated by measuring the longest width, length, and height and multiplying them. Compression relief was confirmed on follow-up MRI at 3 months after surgery, and the residual tumor size was also evaluated.

### Automated Perimetry

Automated perimetry was conducted using the central 30 to 2 Swedish interactive threshold algorithm (SITA) on a visual field analyzer (Humphrey Visual Field Analyzer II; Carl Zeiss Meditec) with a Goldmann size III stimulus on a 31.5-apositlb background. The mean deviation (MD) and pattern SD (PSD) were analyzed. In addition, as visual field loss in chiasmal compression is usually more significant in the temporal field, the average visual sensitivity of the temporal hemifield was calculated in 1/Lambert scale and analyzed. Visual field sensitivity was recorded for each point using the decibel (dB) [ $10 \cdot \log(1/\text{Lambert})$ ]. The unlogged 1/Lambert at each test location was calculated by dividing the decibel unit by 10 and then unlogging it.

### Optical Coherence Tomography

OCT imaging was conducted after pupil dilation using spectral-domain OCT (Cirrus software version 4.5.1.11; Carl Zeiss Meditec).

RNFL thickness measurements were obtained using the optic disc cube  $200 \times 200$  protocol. Peripapillary RNFL thickness parameters were automatically calculated by the software, including average thickness and each quadrant thickness (superior, temporal, inferior, and nasal).

GCC was defined as the combination of nerve fiber, ganglion cell, and inner plexiform layers.<sup>19</sup> Vertical and horizontal cross-sectional images of the macula involving the foveola were obtained using the macular cube  $512 \times 128$  protocol. The GCC area was measured using the polygonal selection tool in imaging software (ImageJ 1.43u, Wayne Rasband, National Institutes of Health; available at <http://rsb.info.nih.gov/ij/index.html>). Measurements in vertical scan (vertical value), horizontal scan (horizontal value), and average value were analyzed.

### Photopic Negative Response

Before the electroretinogram (ERG) recordings, the pupils were confirmed to be maximally dilated to approximately 8 mm in diameter after topical application of 1% tropicamide and 2.5% phenylephrine hydrochloride. Subjects underwent light adaptation by means of a white background light of 31.9 candela ( $\text{cd}/\text{m}^2$ ) for 10 minutes. A bipolar contact lens electrode (Burian-Allen ERG electrode; Hansen Ophthalmic Laboratories, Iowa City, IA) was used. The ground electrode was placed on the earlobe. Full-field light stimulation was then produced, using the Ganzfeld dome. A photostimulator (Grass PS22; Grass-Telefactor; Astro-Med, Inc., West Warwick, RI) was used to generate light stimuli, a white stimulus applied at an intensity of 2.4  $\text{cd}/\text{m}^2$  under a 31.9  $\text{cd}/\text{m}^2$  white background illumination.<sup>20</sup> ERG was recorded (UTAS-E3000 system; LKC Technologies, Inc., Gaithersburg, MD). The duration of the stimulation was limited to less than 5 ms. The

PhNR amplitude was measured from the baseline to the negative trough between the cone b-wave and the i-wave.<sup>17</sup> To reduce the variations of the PhNR amplitude among individuals, the ratio of the PhNR amplitude to the b-wave (PhNR/b-wave ratio) were evaluated.

### Statistical Analysis

Mann-Whitney *U* test was conducted to compare parameters of SAP, OCT measurements, and PhNR between the normal control and the patient groups. Wilcoxon signed rank test was conducted to compare changes of parameters between before and 3 months after surgery in the patient group.

Spearman's correlation and linear regression analyses were conducted to evaluate the relationship between RNFL thickness, GCC area, PhNR/b-wave ratio, and mean deviation and temporal visual field sensitivity. As the mean deviation was recorded in decibel, which is a logarithmic unit, in addition to the linear regression, a logarithmic regression was conducted between RNFL thickness, GCC area, PhNR/b-wave ratio, and mean deviation.<sup>21,22</sup>

Mean deviation and temporal visual field sensitivity was treated as the dependent variable and the others were treated as the independent variable in regression analysis.

Statistical analysis was conducted, using statistical software (SPSS version 15.0 for Windows; SPSS Inc., Chicago, IL). All tests were two-tailed and  $P < 0.05$  was considered statistically significant.

## RESULTS

### General Characteristics

The average age of patients was  $58.47 \pm 12.37$  years in patients and  $53.60 \pm 8.43$  years in age-matched normal controls ( $P = 0.122$ ). The patients had a diagnosis of pituitary adenoma (15 patients), craniopharyngioma (two patients) and meningioma (one patient). The average tumor volume was  $15.21 \pm 5.76 \text{ cm}^3$  before and  $1.28 \pm 2.44 \text{ cm}^3$  after surgery. Complete or near complete decompression of the anterior visual pathways was observed in all patients on the MRI performed after surgery.

### Visual Fields Outcome

MD showed a significant improvement from  $-16.75 \pm 9.04$  dB before surgery to  $-9.91 \pm 7.08$  dB at 3 months after surgery ( $P = 0.003$ ). Temporal visual field sensitivity also showed a significant improvement from  $95.17 \pm 213.90$  1/Lambert (1/L) to  $193.33 \pm 286.22$  1/L (Table 1).

### Preoperative OCT and PhNR Parameters

RNFL thickness around the optic nerve head measured preoperatively was reduced in all four quadrants and average value in the patients compared with the normal controls and significant except nasal quadrant (Table 1).

GCC area measurements in vertical scan, horizontal scan, and their average were reduced significantly in the patients compared with the normal controls (Table 1).

PhNR amplitude and PhNR/b-wave amplitude ratio were also reduced significantly in the patients compared with the normal controls. However, the difference of the b-wave amplitude was not significant between the patients and the normal controls (Table 1).

### Correlation between OCT, PhNR, and Visual Field Outcome

Preoperative RNFL thickness of superior and temporal quadrant correlated significantly with postoperative MD in Spearman's correlation and regression analysis. RNFL thickness of temporal quadrant and average value also correlated significantly with postoperative temporal visual field sensitivity

TABLE 1. Changes of LogMAR VA, MD, PSD, RNFL Thickness, GCC Area, and PhNR/b-Wave Ratio

Variable			P Value, Control versus Preoperative		Postoperative 3 Mo	P Value, Pre- versus Postoperative
	Control	Preoperative				
Age, y	53.60 ± 8.43	56.75 ± 9.83	0.122			
VA, LogMAR	0.00 ± 0.00	0.41 ± 0.46	0.000†††		0.35 ± 0.36	1.000
Visual field test						
MD, dB	-0.08 ± 0.39	-16.75 ± 9.04	0.000†††		-9.91 ± 7.08	0.003**
PSD, dB	1.43 ± 0.27	9.59 ± 4.62	0.000†††		8.75 ± 4.99	0.569
Temporal visual field, I/L	1157.14 ± 203.13	95.17 ± 213.90	0.000†††		193.33 ± 286.22	0.010*
Retinal nerve fiber layer thickness, μM						
Superior	114.66 ± 12.55	100.12 ± 16.58	0.017†		95.93 ± 19.37	0.114
Temporal	69.73 ± 11.00	49.50 ± 10.78	0.000†††		49.05 ± 10.96	0.614
Inferior	127.86 ± 9.00	117.56 ± 14.22	0.024†		108.06 ± 14.40	0.001**
Nasal	64.26 ± 9.72	60.50 ± 10.72	0.404		57.12 ± 10.50	0.092
Average	91.93 ± 9.67	81.92 ± 8.80	0.008††		77.65 ± 9.39	0.017*
Ganglion cell complex area, mm <sup>2</sup>						
Horizontal area	0.286 ± 0.012	0.216 ± 0.024	0.000†††		0.205 ± 0.031	0.019*
Vertical area	0.305 ± 0.011	0.240 ± 0.025	0.000†††		0.226 ± 0.033	0.062
Average	0.295 ± 0.008	0.227 ± 0.023	0.000†††		0.213 ± 0.028	0.037*
Photopic negative response						
b-wave amplitude, μN	55.92 ± 14.33	50.96 ± 23.89	0.215		54.06 ± 16.68	0.373
PhNR amplitude, μN	26.62 ± 7.55	20.26 ± 9.43	0.043†		19.66 ± 11.17	0.859
PhNR/b-wave ratio	0.48 ± 0.13	0.35 ± 0.09	0.012†		0.27 ± 0.15	0.422

† P < 0.05; †† P < 0.01; ††† P < 0.001; Mann-Whitney test.  
 \* P < 0.05; \*\* P < 0.01; Wilcoxon signed rank test.

(Table 2, Fig. 1). Temporal RNFL thickness showed the strongest correlation with postoperative visual field.

All GCC area measurements before surgery in vertical, horizontal scan, and average value were correlated significantly with postoperative MD and temporal visual field sensitivity (Table 2, Fig. 1).

PhNR/b-wave amplitude ratio correlated significantly with postoperative MD and temporal visual field sensitivity.

Representative cases with good and bad visual outcomes involving their preoperative measurements are shown in Figure 2.

DISCUSSION

The improvement in visual function after surgical decompression of the optic nerve and chiasm for pituitary tumors is highly

variable. The degree of retrograde degeneration to the RGCs is considered an important determinant of final visual outcome. OCT and PhNR are useful tools to assess the structural and functional damage of RGCs, both objectively and quantitatively.

Prognostic Value of RNFL Thickness

In two recent studies, the prognostic value of RNFL thickness was assessed and evidenced preoperatively measured RNFL thickness as a useful indicator for predicting visual outcome.<sup>8,9</sup> Danesh-Meyer et al.<sup>8</sup> described that patients with normal preoperative RNFL had significant improvement in VA and VF at 6 weeks after surgery, whereas patients with thin RNFL did not improve. Jacob et al.<sup>9</sup> described that the odds of complete recovery after 3 months from the initial VF defect was multi-

TABLE 2. Spearman's Correlation Coefficients and Regression Analysis between Preoperative Measurements and Postoperative Visual Field Test

Variables (Preoperative Measurements)	Mean Deviation (dB) (Postoperative 3 Mo)						Temporal Visual Fields (I/L) (Postoperative 3 Mo)			
	Spearman's		Linear Regression		Log Regression		Spearman's		Linear Regression	
	R	P	R <sup>2</sup>	P	R <sup>2</sup>	P	R	P	R <sup>2</sup>	P
RNFL thickness										
Superior	0.447	0.037*	0.248	0.018*	0.244	0.019*	0.408	0.060	0.138	0.089
Inferior	0.463	0.030*	0.091	0.173	0.094	0.166	0.417	0.054	0.213	0.031*
Nasal	0.269	0.226	0.003	0.812	0.000	0.965	0.188	0.402	0.030	0.439
Temporal	0.625	0.002**	0.308	0.007**	0.274	0.012*	0.599	0.003**	0.547	0.000***
Average	0.553	0.008**	0.169	0.058	0.165	0.061	0.453	0.034*	0.241	0.020*
GCC area										
Horizontal	0.789	0.000***	0.429	0.002**	0.416	0.003**	0.821	0.000***	0.785	0.000***
Vertical	0.761	0.000***	0.411	0.003**	0.389	0.004**	0.765	0.000***	0.775	0.000***
Average	0.835	0.000***	0.440	0.002**	0.424	0.003**	0.863	0.000***	0.839	0.000***
PhNR										
PhNR/b ratio	0.581	0.009**	0.230	0.038*	0.276	0.021*	0.741	0.000***	0.556	0.000***

\* P < 0.05; \*\* P < 0.01; \*\*\* P < 0.001.

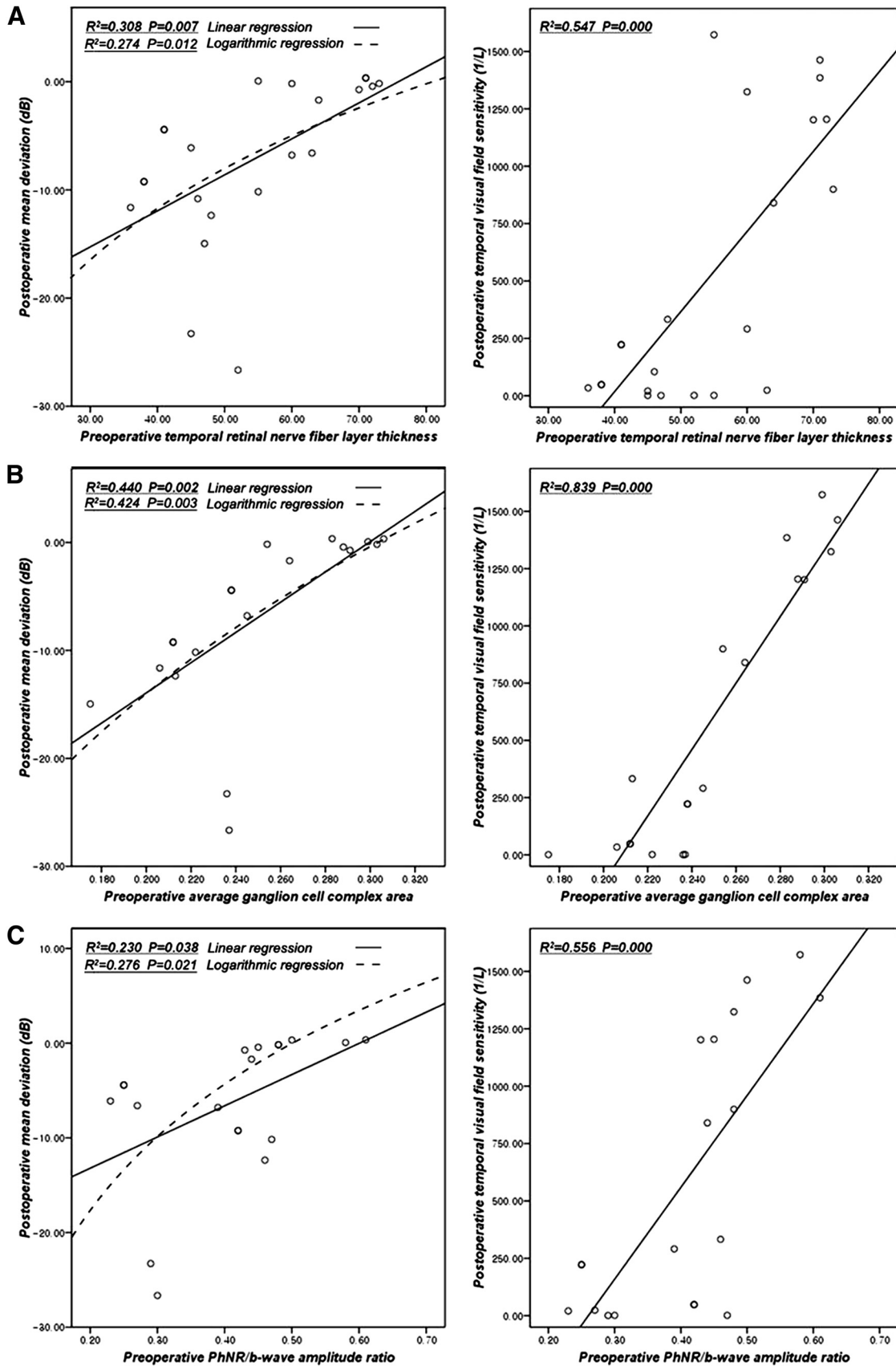
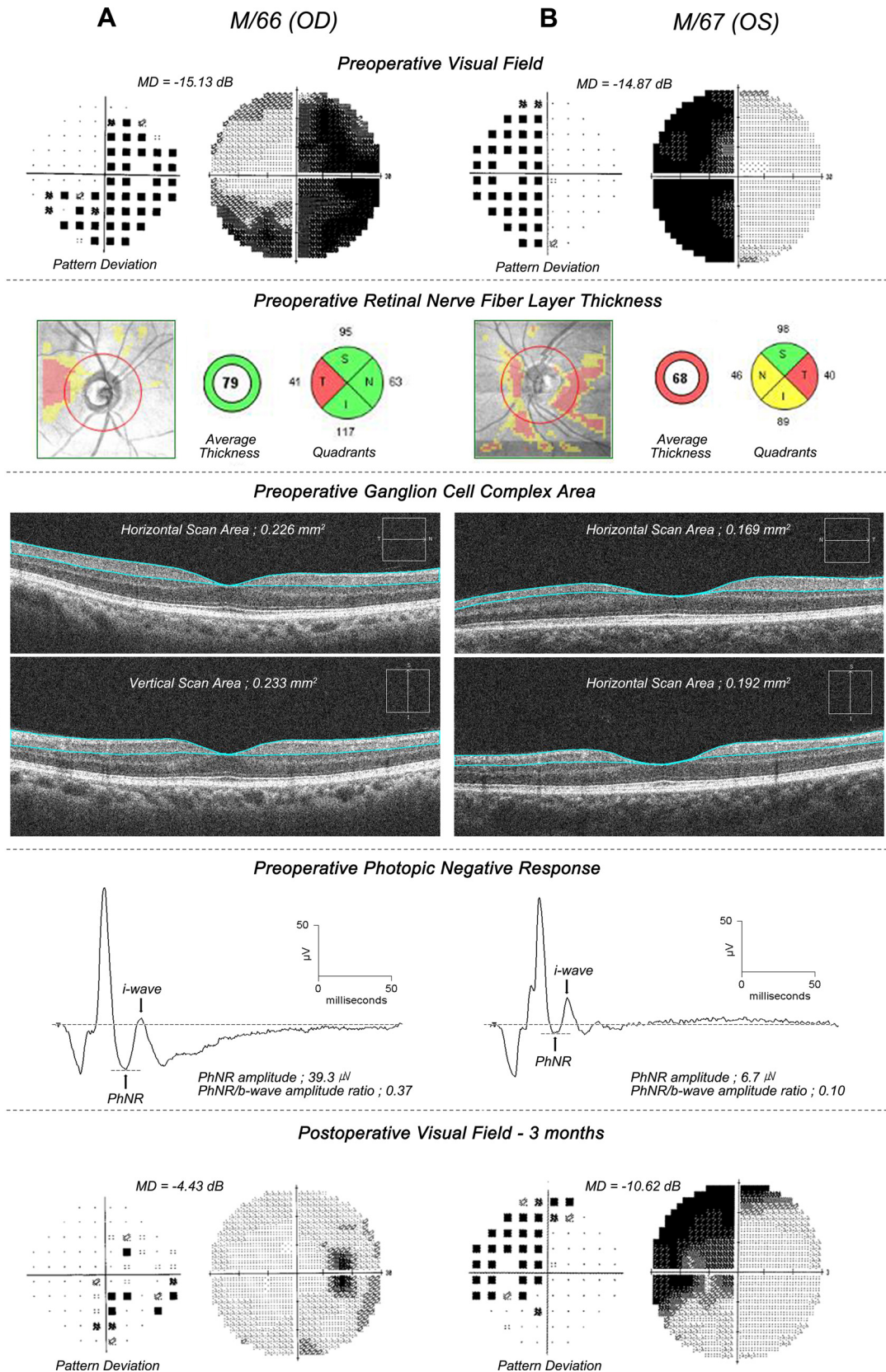


FIGURE 1. Scatterplot of postoperative mean deviation, temporal visual field sensitivity, and temporal RNFL thickness (A), average ganglion cell complex area (B), and PhNR/b-wave amplitude ratio (C).





**FIGURE 2.** Representative cases with good (A) and bad (B) visual outcomes. A 66-year-old man (A) and a 67-year-old man (B) were diagnosed with pituitary adenoma and underwent transphenoidal adenectomy. In preoperative assessment, visual field of patient A was worse than that of patient B, although the ganglion cell measurements including RNFL thickness, GCC area, and the PhNR of patient A were better than those of patient B. In postoperative assessment, 3 months after surgery, patient A showed a significant visual improvement. Patient B also showed a visual improvement, but not as much as patient A.

plied by 1.29 for each increase by 1  $\mu\text{m}$  of mean RNFL and 6.31 by 1  $\mu\text{m}$  of inferior RNFL in their mixed logistic regression model.

In the present study, preoperatively assessed RNFL thickness in all three quadrants and average values except nasal quadrant were correlated significantly with postoperative visual field and suggested that RNFL thickness measurements could be a prognostic indicator. Among them, temporal RNFL thickness showed the strongest correlation with visual field outcome. It is thought because in temporal visual fields, the papillomacular bundle area is the most severely affected portion and they enter the optic disc through the temporal quadrant.

### Prognostic Value of Ganglion Cell Complex Measurements

RNFL thinning reflects axonal degeneration of optic nerve fibers secondary to compression,<sup>9</sup> but does not directly reflect the loss of retinal ganglion cells. Therefore in this study we selectively measured the GCC area from the macular scan to assess the retinal ganglion cell loss as well as axonal degeneration. Preoperatively measured ganglion cell complex area in horizontal, vertical macular scan, and average values were correlated significantly with postoperative visual field and evidenced even higher correlation than RNFL thickness.

In glaucoma studies, Mori et al.<sup>23</sup> showed that selective measurement of the ganglion cell complex layer by spectral-domain OCT improves diagnostic performance of the macular structural analysis for glaucoma diagnosis. Tan et al.<sup>19</sup> measured ganglion cell complex using Fourier-domain OCT in glaucoma patients and showed that ganglion cell mapping and pattern analysis improved diagnostic power. The improved diagnostic power of macular ganglion cell complex imaging is on par with, and complementary to, peripapillary nerve fiber layer imaging.

In the present study, results suggested that GCC measurements involving retinal ganglion cell layer and nerve fiber layer could be another useful prognostic indicator and had a stronger correlation with visual outcome compared with RNFL thickness.

### Prognostic Value of PhNR

The PhNR is strongly attenuated in primate eyes with experimentally-induced glaucoma and in eyes intravitreally injected with tetrodotoxin, a blocker of the neural activity of retinal ganglion cells and their axons.<sup>24,25</sup> It has been demonstrated that the PhNR was reduced in patients with optic nerve and retinal disease that affect mainly the retinal ganglion cells and nerve fiber layer.<sup>12-18</sup> Gotoh et al.<sup>17</sup> conducted full field ERG and PhNR in 10 patients with optic nerve atrophy induced by compression, trauma, or inflammation. The amplitudes of the rod and cone cell responses in full-field electroretinograms of the affected eyes were not different from those of the corresponding waves of the contralateral unaffected eyes or control eyes. In contrast, the amplitude of the PhNR was significantly smaller in the affected eyes than in the contralateral or control eyes.

To the best of our knowledge, this is the first report that investigated the PhNR as a prognostic indicator in patients with chiasmal compression. Preoperatively assessed PhNR/b-wave amplitude ratios were correlated significantly with postoperative visual field and suggested that PhNR can be used to predict visual outcome.

The pattern electroretinogram (PERG) is another response that reflects the activity of ganglion cells and their axons.<sup>26,27</sup> The cellular origin of negative potentials of the PERG is similar to that of the PhNR.<sup>18</sup> In addition, Parmar et al.<sup>27</sup> described the

PERG as a useful visual prognostic indicator in chiasmal compression. Monteiro et al.<sup>28</sup> also concluded that PERG amplitude and OCT thickness measurements were significantly related to visual field loss. However, from a practical standpoint, PhNR has several advantages compared with PERG that do not require refractive correction, clear ocular media, and exact foveal placement.

### Limitation of the Present Study

The limitation of this study was its small number of participants. Further investigation with greater numbers of individuals may assist to provide a more accurate prognosis in an individual patient.

### Conclusions

An eye with the more demonstrable structural deterioration as shown by reduced RNFL thickness and GCC area, and retinal ganglion cell dysfunction as shown by decreased PhNR/b-wave amplitude ratio were associated with the worse visual fields outcome. RNFL thickness and GCC area measurements using OCT and PhNR/b-wave ratio could be a useful prognostic indicator in the preoperative assessment of chiasmal compression.

### References

1. Elkington S. Pituitary adenoma. Preoperative symptomatology in a series of 260 patients. *Br J Ophthalmol.* 1968;52:322-328.
2. Holder GE. The pattern electroretinogram in anterior visual pathway dysfunction and its relationship to the pattern visual evoked potential: a personal clinical review of 743 eyes. *Eye.* 1997;11:924-934.
3. Laws ER Jr, Trautmann JC, Hollenhorst RW Jr. Transsphenoidal decompression of the optic nerve and chiasm: visual results in 62 patients. *J Neurosurg.* 1977;46:717-722.
4. Brececi J. A VEP study of the visual pathway function in compressive lesions of the optic chiasm. Full-field versus half-field stimulation. *Electroencephalogr Clin Neurophysiol.* 1992;84:209-218.
5. Kanmori A, Nakamura M, Matsui N, et al. Optical coherence tomography detects characteristic retinal nerve fiber layer thickness corresponding to band atrophy of the optic discs. *Ophthalmology.* 2004;111:2278-2283.
6. Monteiro ML, Moura FC, Medeiros FA. Diagnostic ability of optical coherence tomography with a normative database to detect band atrophy of the optic nerve. *Am J Ophthalmol.* 2007;143:896-899.
7. Danesh-Meyer HV, Carroll SC, Foroozan R, et al. Relationship between retinal nerve fiber layer and visual field sensitivity as measured by optical coherence tomography in chiasmal compression. *Invest Ophthalmol Vis Sci.* 2006;47:4827-4835.
8. Danesh-Meyer HV, Papchenko T, Savino PJ, Law A, Evans J, Gamble GD. In vivo retinal nerve fiber layer thickness measured by optical coherence tomography predicts visual recovery after surgery for parachiasmal tumors. *Invest Ophthalmol Vis Sci.* 2008;49:1879-1885.
9. Jacob M, Raverot G, Jouanneau E, et al. Predicting visual outcome after treatment of pituitary adenoma with optical coherence tomography. *Am J Ophthalmol.* 2009;147:64-70.
10. Spliebers W, Reis-Falcao F, Smith R, Hogg C, Arden GB. The human ERG evoked by a Ganzfeld stimulator powered by red and green light emitting diodes. *Clin Vision Sci.* 1993;8:21-39.
11. Viswanathan S, Frishman LJ, Robson JG, Harwerth RS, Smith EL 3rd. The photopic negative response of the macaque electroretinogram: reduction by experimental glaucoma. *Invest Ophthalmol Vis Sci.* 1999;40:1124-1136.
12. Viswanathan S, Frishman LJ, Robson JG, Walters JW. The photopic negative response of the flash electroretinogram in primary open angle glaucoma. *Invest Ophthalmol Vis Sci.* 2001;42:514-522.
13. Rangaswamy NV, Frishman LJ, Dorotheo EU, et al. Photopic ERGs in patients with optic neuropathies: comparison with primate ERGs after pharmacological blockade of inner retina. *Invest Ophthalmol Vis Sci.* 2004;45:3827-3837.

14. Machida S, Toba Y, Ohtaki A, Gotoh Y, Kaneko M, Kurosaka D. Photopic negative response of focal electroretinograms in glaucomatous eyes. *Invest Ophthalmol Vis Sci.* 2008;49:5636-5644.
15. Machida S, Gotoh Y, Tanaka M, Tazawa Y. Predominant loss of the photopic negative response in central retinal artery occlusion. *Am J Ophthalmol.* 2004;137:938-940.
16. Colotto A, Falsini B, Salgarello T, Larossi G, Galan ME, Scullica L. Photopic negative response of the human ERG: losses associated with glaucomatous damage. *Invest Ophthalmol Vis Sci.* 2000;41:2205-2211.
17. Gotoh Y, Machida S, Tazawa Y. Selective loss of the photopic negative response in patients with optic nerve atrophy. *Arch Ophthalmol.* 2004;122:341-346.
18. Tamada K, Machida S, Yokoyama D, Kurosaka D. Photopic negative response of full-field and focal macular electroretinograms in patients with optic nerve atrophy. *Jpn J Ophthalmol.* 2009;53:608-614.
19. Tan O, Chopra V, Lu AT, et al. Detection of macular ganglion cell loss in glaucoma by Fourier-domain optical coherence tomography. *Ophthalmology.* 2009;116:2305-2314.
20. Rangswamy NV, Shirato S, Kaneko M, Digby BI, Robson JG, Frishman LJ. Effects of spectral characteristics of Ganzfeld stimuli on the photopic negative response (PhNR) of the ERG. *Invest Ophthalmol Vis Sci.* 2007;48:4818-4828.
21. Hood DC, Kardon RH. A framework for comparing structural and functional measures of glaucomatous damage. *Prog Retin Eye Res.* 2007;26:688-710.
22. Hood DC, Greenstein VC, Odel JG, et al. Visual field defects and multifocal visual evoked potentials: evidence of a linear relationship. *Arch Ophthalmol.* 2002;120:1672-1681.
23. Mori S, Hangai M, Sakamoto A, Yoshimura N. Spectral-domain optical coherence tomography measurement of macular volume for diagnosing glaucoma. *J Glaucoma.* 2010;19:528-534.
24. Narahashi T. Chemicals as tools in the study of excitable membranes. *Physiol Rev.* 1974;54:813-889.
25. Bloomfield SA. Effect of spike blockade on the receptive-field size of amacrine and ganglion cells in the rabbit retina. *J Neurophysiol.* 1996;75:1878-1893.
26. Maffei L, Fiorentini A, Bisti S, Hollander H. Pattern ERG in the monkey after section of the optic nerve. *Exp Brain Res.* 1985;59:423-425.
27. Parmar DN, Sofat A, Bowman R, Bartlett JR, Holder GE. Visual prognostic value of the pattern electroretinogram in chiasmal compression. *Br J Ophthalmol.* 2000;84:1024-1026.
28. Monteiro ML, Cunha LP, Costa-Cunha LV, Maia OO Jr, Oyamada MK. Relationship between optical coherence tomography, pattern electroretinogram and automated perimetry in eyes with temporal hemianopia from chiasmal compression. *Invest Ophthalmol Vis Sci.* 2009;50:3535-3541.